ORDINE PROVINCIALE
DEI MEDICI CHIRURGHI E
DEGLI ODONTOIATRI
DI VENEZIA



SABATO 17 MAGGIO 2025

Sala Convegni Caterina Boscolo
OMCeO Venezia | Via Mestrina 86 Mestre

IL PAZIENTE DIGITALE NELLO STUDIO DENTISTICO















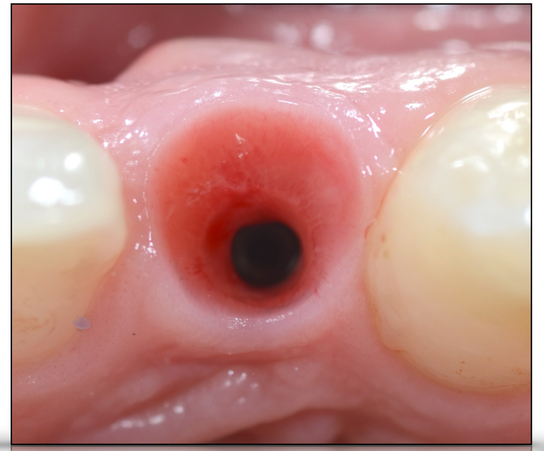















Review J Prosthodont 2023 Jul;32(6):482-488. doi: 10.1111/jopr.13603. Epub 2022 Sep 27.

Centric relation: A needed reference position

Gary R Goldstein 1
Affiliations expand

• PMID: 36074517 DOI: 10.1111/jopr.13603

Abstract

Purpose: Centric relation (CR) is a universally recognized term and an acceptable reference position with a long history of success. The problem is that there is little consensus as to its definition or the method of recording it, and this has created an uprising to abolish it.

Methods: A review of pertinent literature related to its definition, method of recording, anatomic considerations, and long-standing principles was conducted.

Results: Centric relation is an established term but there are valid concerns over its definition and method of recording. There is consensus on using it as a restorative position in a patient in need of full-arch reconstruction, and there is no substantive clinical research to contradict this. If a clinician decides to use a different position, it should have a different name.

Conclusions: Centric relation is a reproducible reference position that can be utilized for diagnostic and restorative dental procedures with substantial scientific evidence to support that premise. There are numerous well-documented techniques, all of which are intermaxillary, that can replicate the position. There is little scientific evidence to support a premise as to where the exact position of the condyle should be in relation to the fossa.

Review J Oral Rehabil
2023 Nov;50(11):1355-1361. doi: 10.1111/joor.13553. Epub 2023 Jul 11.

Centric relation-A biological perspective of a technical concept

Daniele Manfredini 1, Carlo Ercoli 2, Carlo E Poggio 2, Fabio Carboncini 1, Marco Ferrari 1
Affiliations expand

• PMID: 37394665 DOI: 10.1111/joor.13553

Abstract

Background: Few terms and concepts have been so extensively debated in dentistry as the words 'centric relation' (CR). Debates involve its biological, diagnostic and therapeutic usefulness.

Methods: A review of the literature on the current concepts on CR as a diagnostic or therapeutic aid in dentistry was provided. Clinical trials assessing the superiority of one CR recording method over the others to identify patients with temporomandibular disorders (diagnostic use) or to manage patients with prosthodontic or orthodontic needs (therapeutic use) were tentatively included.

Results: Due to the absence of literature addressing either of the above targets, a comprehensive overview was provided. The diagnostic use of CR as a reference position to identify the correct position of the temporomandibular joint condyle within the glenoid fossa is not supported and lacks anatomical support. From a therapeutic standpoint, the use of CR can be pragmatically useful in prosthodontics as a maxillo-mandibular reference position when occlusal re-organization is warranted and/or when the position of maximum intercuspation is no longer available.

Conclusions: The derived occlusal goals from a diagnostic misuse of CR are generally the result of circular reasoning, that is a technique is based on the recording of a certain condylar position that is believed to be 'ideal' and the treatment is considered successful when such position is shown by the specific instrument that was manufactured for that purpose. The term 'Centric Relation' might be replaced with the term 'Maxillo-Mandibular Utility Position'.



Review J Oral Rehabil
2021 Sep;48(9):1050-1055. doi: 10.1111/joor.13215. Epub 2021 Jul 3.

Centric relation critically revisited-What are the clinical implications?

Adriaan J J Zonnenberg 1, Jens Christoph Türp 2, Charles S Greene 3
Affiliations expand
• PMID: 34164832 DOI: 10.1111/joor.13215

Abstract

Purpose of the article: Centric relation is a dental term that has undergone many alterations over the years, which in turn have led to significant clinical controversies. These continuing changes in the meaning of the term CR have not only led to confusion, but they also have resulted in a variety of unnecessary diagnostic and therapeutic procedures. Analysis of the dental literature reveals ongoing misunderstanding and disagreement regarding that term among both clinicians and academic dentists.

Materials and methods: A search of the PubMed database was performed with the following search terms: "centric relation", "masticatory muscles", "maxillomandibular relationship" and "condylar position." Relevant literature from the past 70 years until the present day was meticulously scrutinised.

Results: As expected, the literature review on the topic of CR revealed a problematic pattern of changing definitions and clinical disagreements, all of which have had a significant impact on the practice of dentistry.

Conclusion: There are semantic, conceptual and practical reasons for concluding that the term 'centric relation' is flawed. Those flaws have a significant impact on dental practice. Based on our analysis, argumentation is provided to conclude that the term 'centric relation' should be abandoned. Instead, it appears that every individual has a unique temporomandibular joint relationship which cannot be described by any singular term. In healthy dentate patients, this relationship is determined by the maximum intercuspation of the teeth and should therefore be considered as biologically acceptable.

Review J Prosthodont
2021 Apr;30(S1):26-33. doi: 10.1111/jopr.13316.

The Relationship Between Centric Occlusion and The Maximal Intercuspal Position and Their Use as Treatment Positions for Complete Mouth Rehabilitation: Best Evidence Consensus Statement

Mathew T Kattadiyil 1, Abdulaziz A Alzaid 2 3, Stephen D Campbell 4
Affiliations expand

• PMID: 33783091 DOI: 10.1111/jopr.13316

Abstract

Purpose: The purpose of this Best Evidence Consensus Statement was to evaluate the existing literature relative to two focus questions: How often does centric occlusion coincide with maximal intercuspal position in dentate and partially dentate populations?; and should centric occlusion or maximal intercuspal positions be equivalent for dentate and partially dentate patients undergoing complete mouth rehabilitation?

Materials and methods: Keywords used in the initial search were: intercuspal position, centric occlusion, centric relation, maximal intercuspal position, prosthodontic rehabilitation, and occlusion. The search was then limited to Systematic Reviews, Randomized Controlled Studies, Meta-analyses and Clinical Trials.

Results: The initial search strategy related to the selected search terms resulted in more than 15,000 articles. When the subsequent search was limited to Systematic Reviews, Randomized Controlled Studies, and Meta-Analysis and Clinical Trials, 313 articles were selected for further analysis.

Conclusions: Review of the literature reveals that most dentate and partially dentate patients do not have coincident centric occlusion and maximal intercuspal position. There is support for coincidence between centric occlusion and maximal intercuspal position as the preferred occlusal relationship in complete mouth rehabilitations. The literature does not report conclusive evidence of adverse prosthodontic outcomes with complete rehabilitations in centric occlusion or maximal intercuspal position in a healthy population. However, there is support for an association between centric occlusion-maximal intercuspal position discrepancies and occlusal instability as well as temporomandibular joint disorders. Hence, it is concluded that partially and completely dentate patients requiring complete mouth rehabilitation should be restored in centric occlusion.

THE GLOSSARY OF PROSTHODONTIC TERMS

Centric Relation

1:the maxillomandibularrelationship in which the condyles articulate with the thinnest avascular portion of their respective disks with the complex in the anterior-superior position against the shapes of the articular em- inencies. This position is independent of tooth contact. This po- sition is clinically discernible when the mandible is directed superior and anteriorly. It is restricted to a purely rotary move- ment about the transverse horizontal axis (GPT-5)

2: the most retruded physiologic relation of the mandible to the maxillae to and from which the individual can make lateral movements. It is a condition that can exist at various degrees of jaw separation. It occurs around the terminal hinge axis (GPT-3)

3: the most retruded relation of the mandible to the maxillae when the condyles are in the most posterior unstrained position in the glenoid fossae from which lateral movement can be made at any given degree of jaw separation (GPT-1)

4: The most posterior relation of the lower to the upper jaw from which lateral movements can be made at a given vertical dimension (Boucher)

5: a maxilla to man- dible relationship in which the condyles and disks are thought to be in the midmost, uppermost position. The position has been difficult to define anatomically but is determined clinically by assessing when the jaw can hinge on a fixed terminal axis (up to 25 mm). It is a clinically determined relationship of the man- dible to the maxilla when the condyle disk assemblies are posi- tioned in their most superior position in the mandibular fossae and against the distal slope of the articular eminence (Ash)

6: the relation of the mandible to the maxillae when the condyles are in the uppermost and rearmost position in the glenoid fossae. This position may not be able to be recorded in the presence of dysfunction of the masticatory system

7: a clinically determined position of the mandible placing both condyles into their anterior uppermost position. This can be determined in patients without pain or derangement in the TMJ (Ramsfjord)

Boucher CO. Occlusion in prosthodontics. J PROSTHET DENT 1953; 3:633-56. Ash MM. Personal communication, July 1993.

Lang BR, Kelsey CC. International prosthodontic workshop on complete denture occlusion. Ann Arbor: The University of Michigan School of Dentistry, 1973.Ramsfjord SP. Personal communication, July 1993.


Come
facciamo?

Qual è la tecnica migliore?







Movimenti liberi



Senza nessuna manipolazione

Il sistema Itaka , acquisisce i dati individuali del paziente



Possiamo elaborare un piano di trattamento sia in fase di diagnosi che di ricostruzione

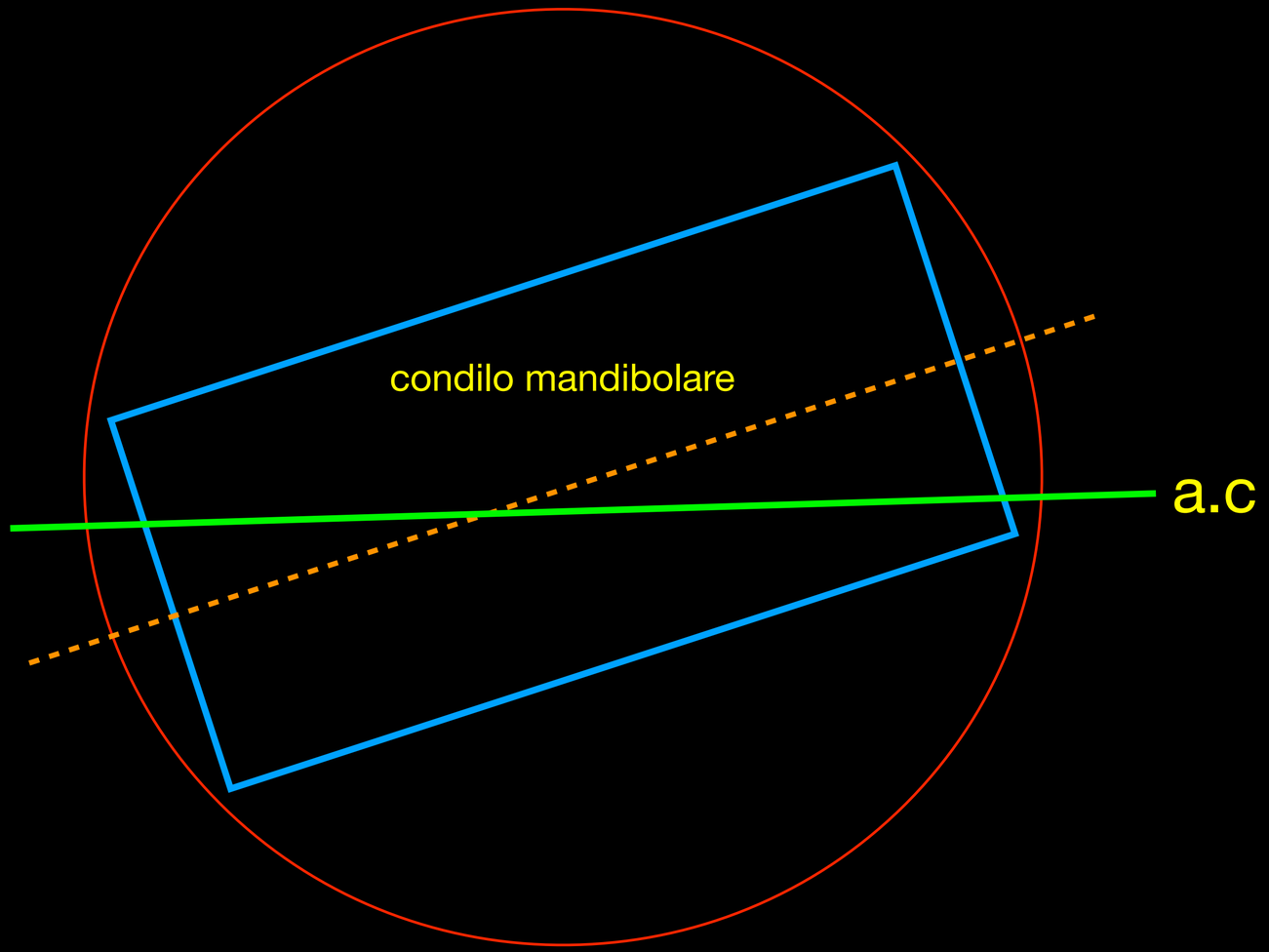
condilo mandibolare
a.c

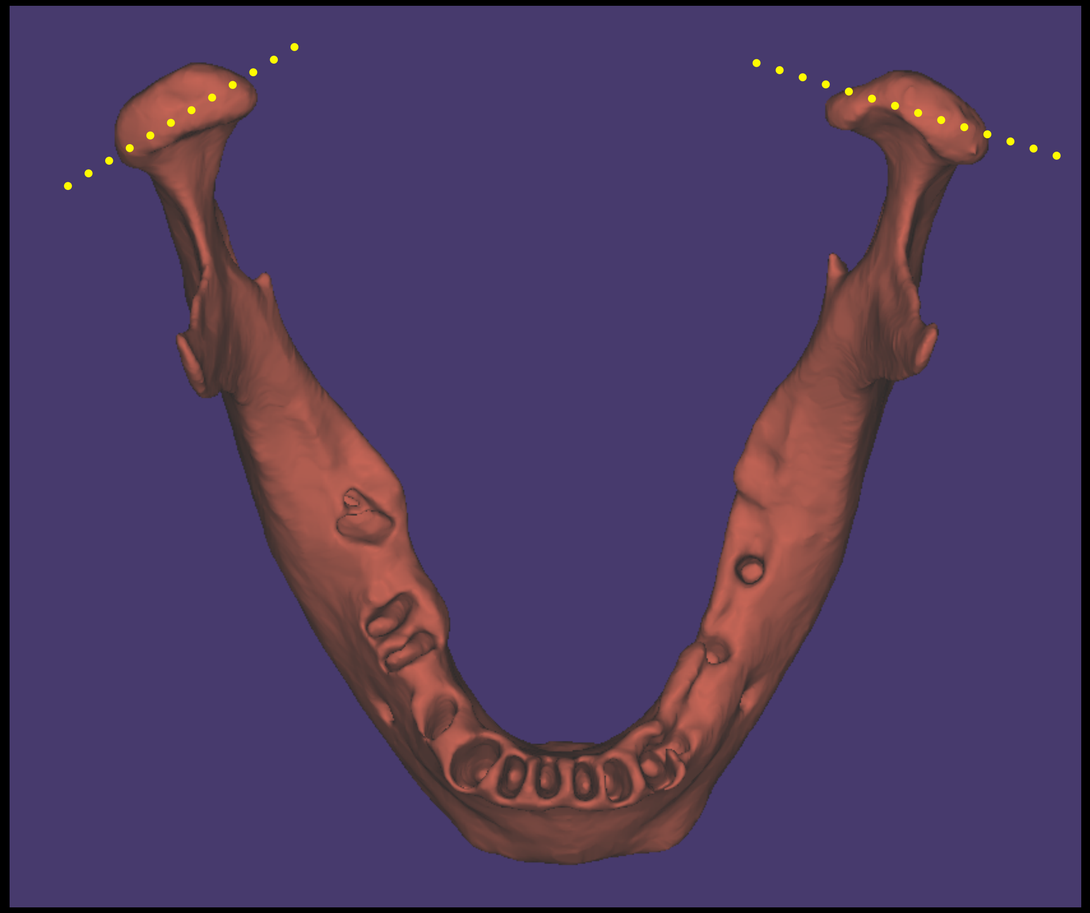

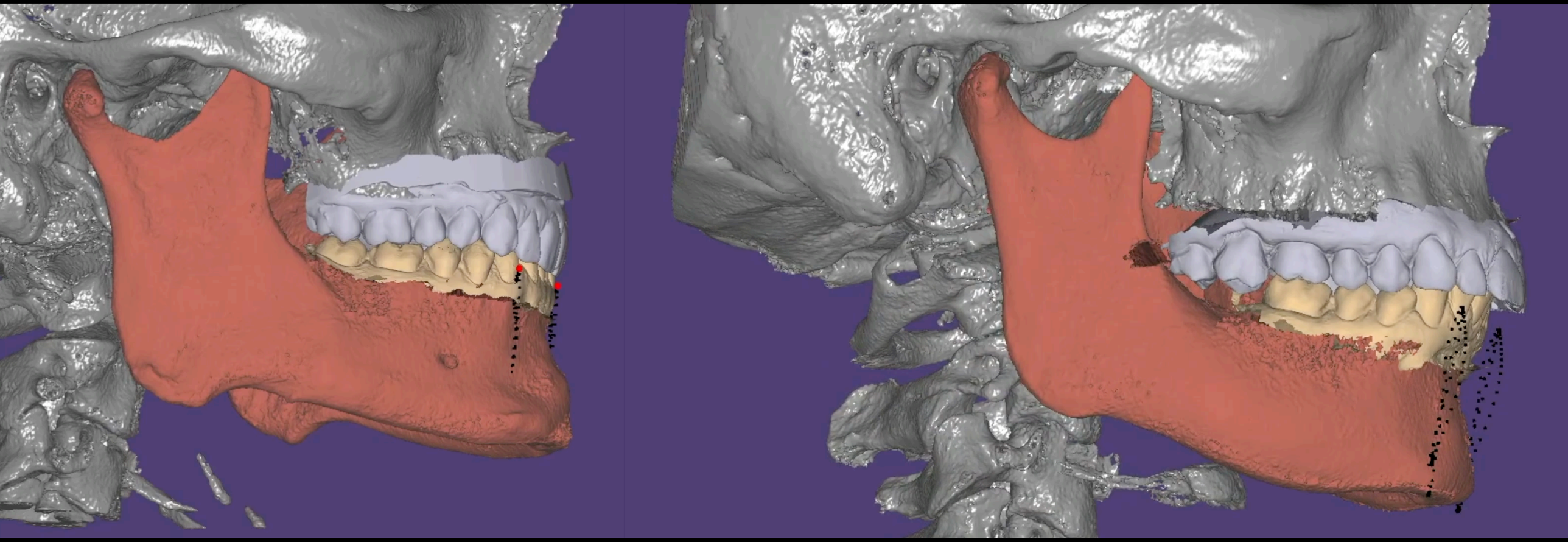

Qual è la tecnica migliore?







Cosa riusciamo a registrare?

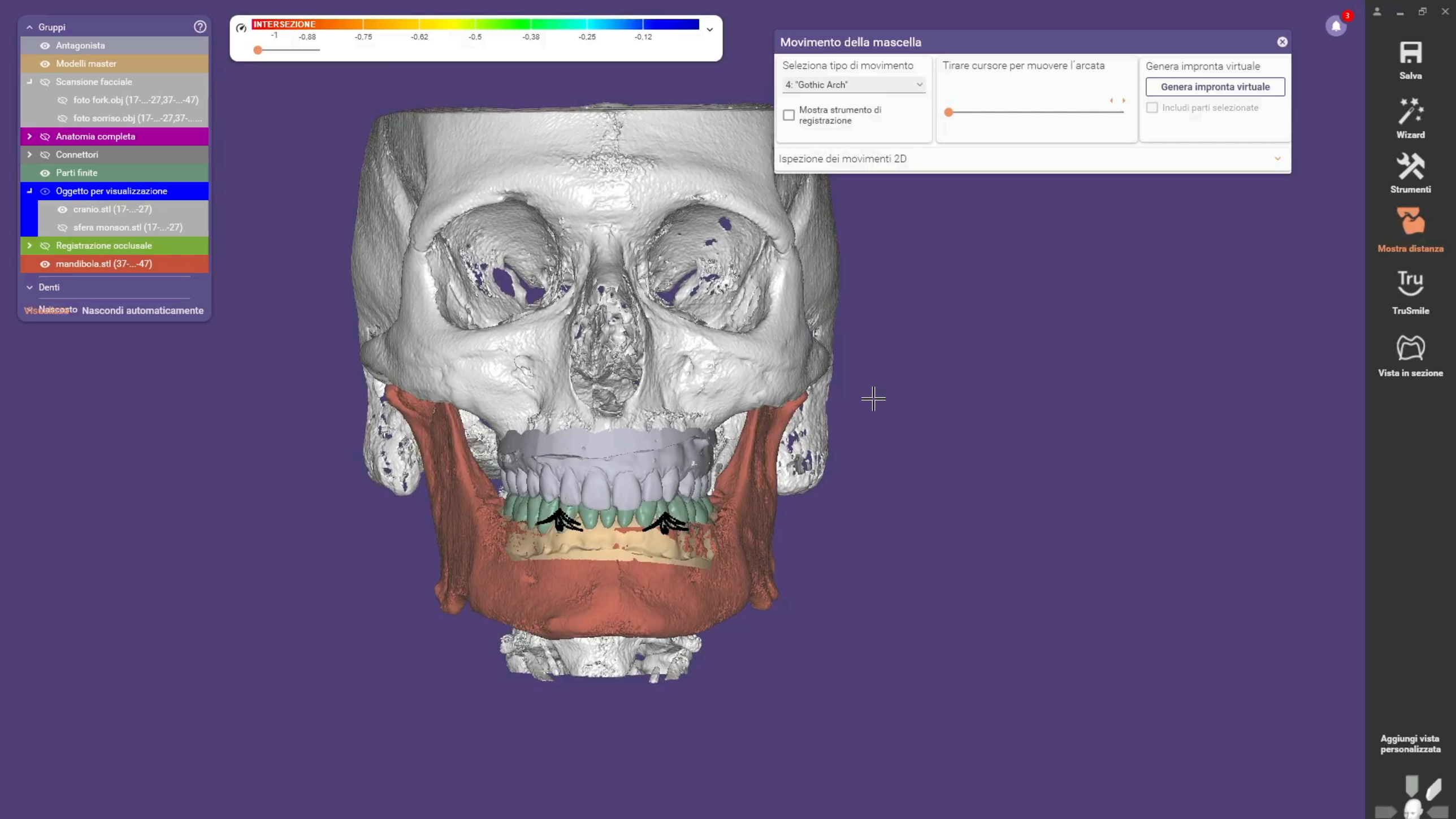
Gruppi
Antagonista
Modelli master
Scansione facciale
foto fork.obj (17-...-27,37-...-47)
foto sorriso.obj (17-...-27,37-.....
Anatomia completa
Connettori
Parti finite
Oggetto per visualizzazione
cranio.stl (17-...-27)
sfera monson.stl (17-...-27)
Registrazione occlusale
mandibola.stl (37-...-47)
Denti
Nascosto
Nascondi automaticamente
INTERSEZIONE
-1
-0,88
-0,75
-0,62
-0,5
-0,38
-0,25
-0,12
Movimento della mascella
Seleziona tipo di movimento
4: "Gothic Arch"
Mostra strumento di registrazione
Tirare cursore per muovere l'arcata
Genera impronta virtuale
Genera impronta virtuale
Includi parti selezionate
Ispezione dei movimenti 2D
Salva
Wizard
Strumenti
Mostra distanza
TruSmile
Vista in sezione
Aggiungi vista personalizzata

Roto-traslazione





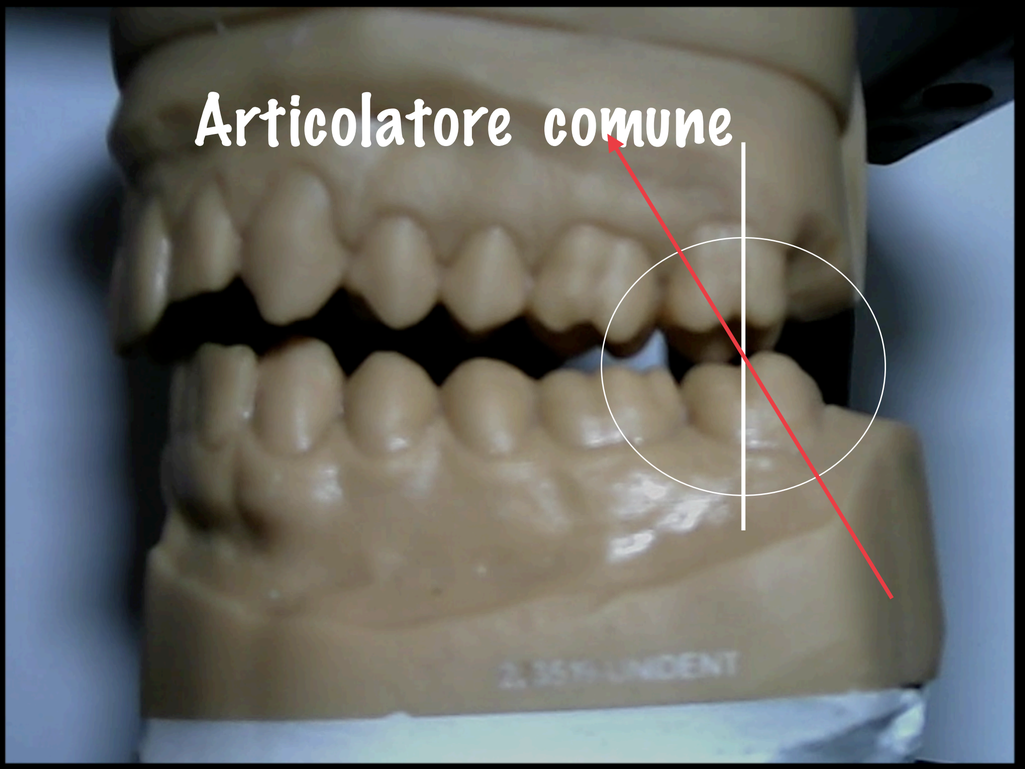
Articolatore comune


Movimento libero registrato e replicato

Confort position

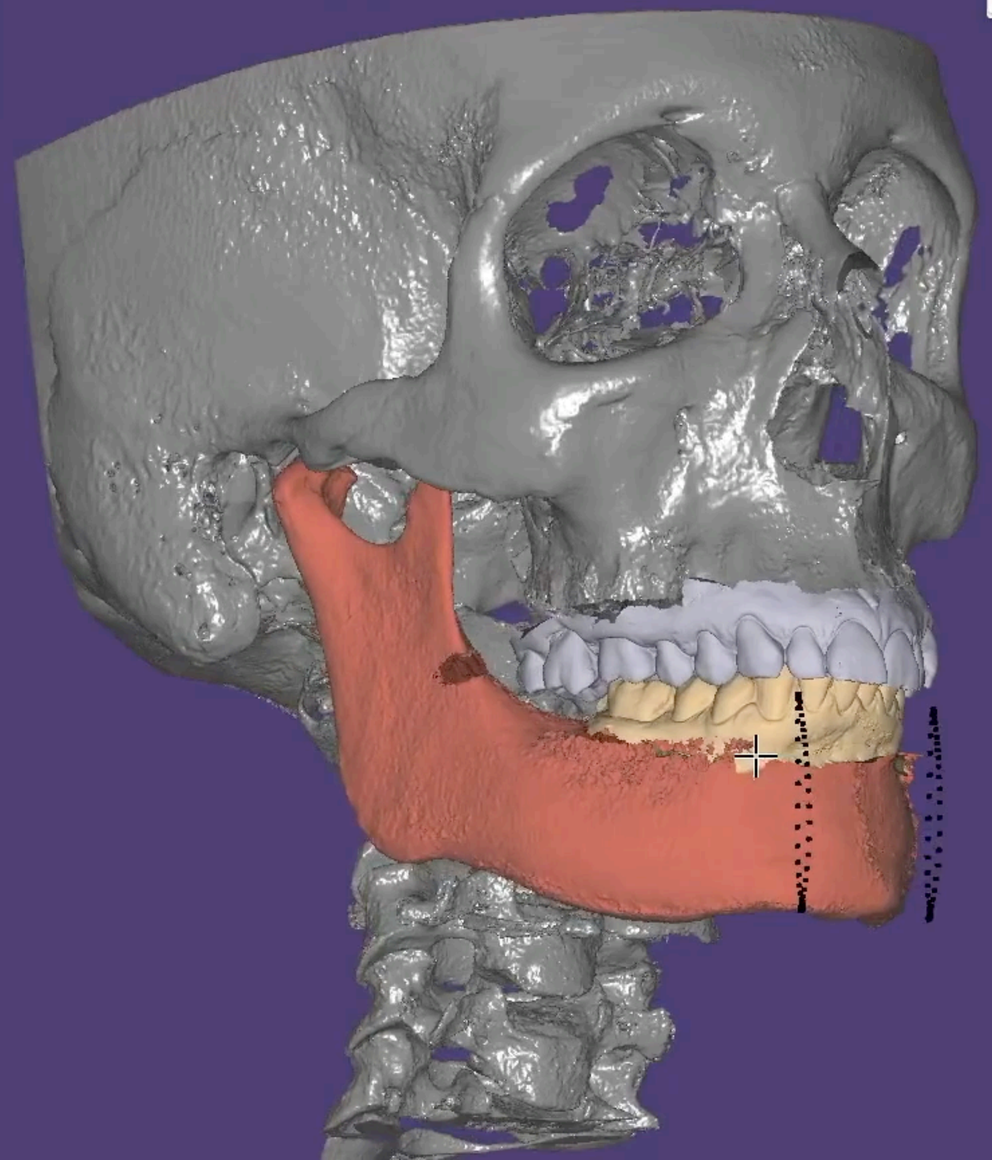

Gruppi
- Antagonista
- Modelli master
- Scansione facciale
- Oggetto per visualizzazione
- Registrazione occlusale
- DICOM (Tac file)
- mandibola.stl (38-...-48)
- Note
- Superficie DICOM (tac)

Denti

Nascosto Nascondi automaticamente

Movimento della mascella

Seleziona tipo di movimento
5: "Comfort Position"
Mostra strumento di registrazione

Tirare cursore per muovere l'arcata

Genera impronta virtuale
Genera impronta virtuale
Includi parti selezionate

Ispezione dei movimenti 2D

Salva
Wizard
Strumenti
Mostra distanza
TruSmile
Visualizzatore DICOM
Vista in sezione
Aggiungi vista personalizzata


Quanto sarà
complicata
tutta questa
procedura?





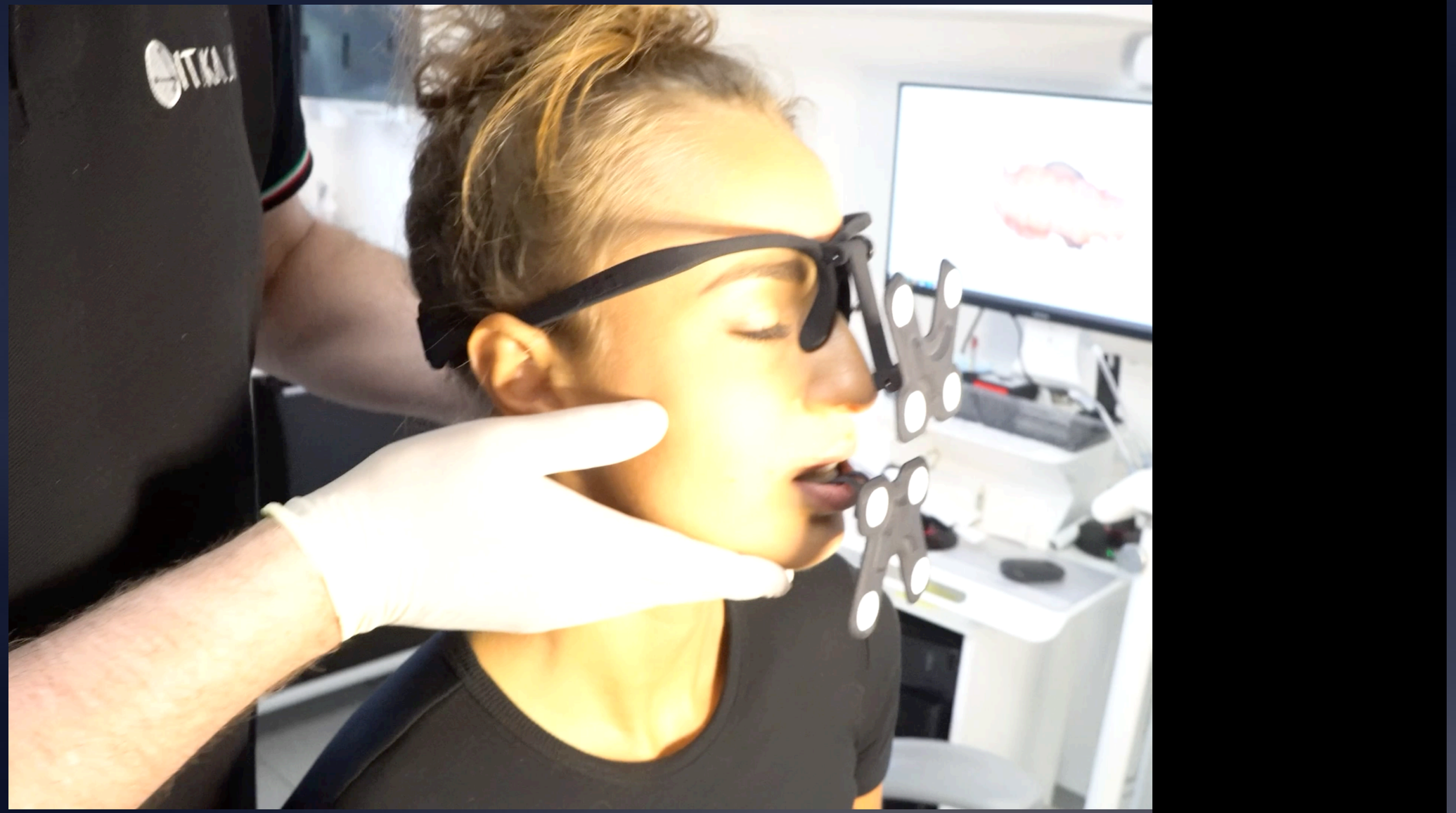

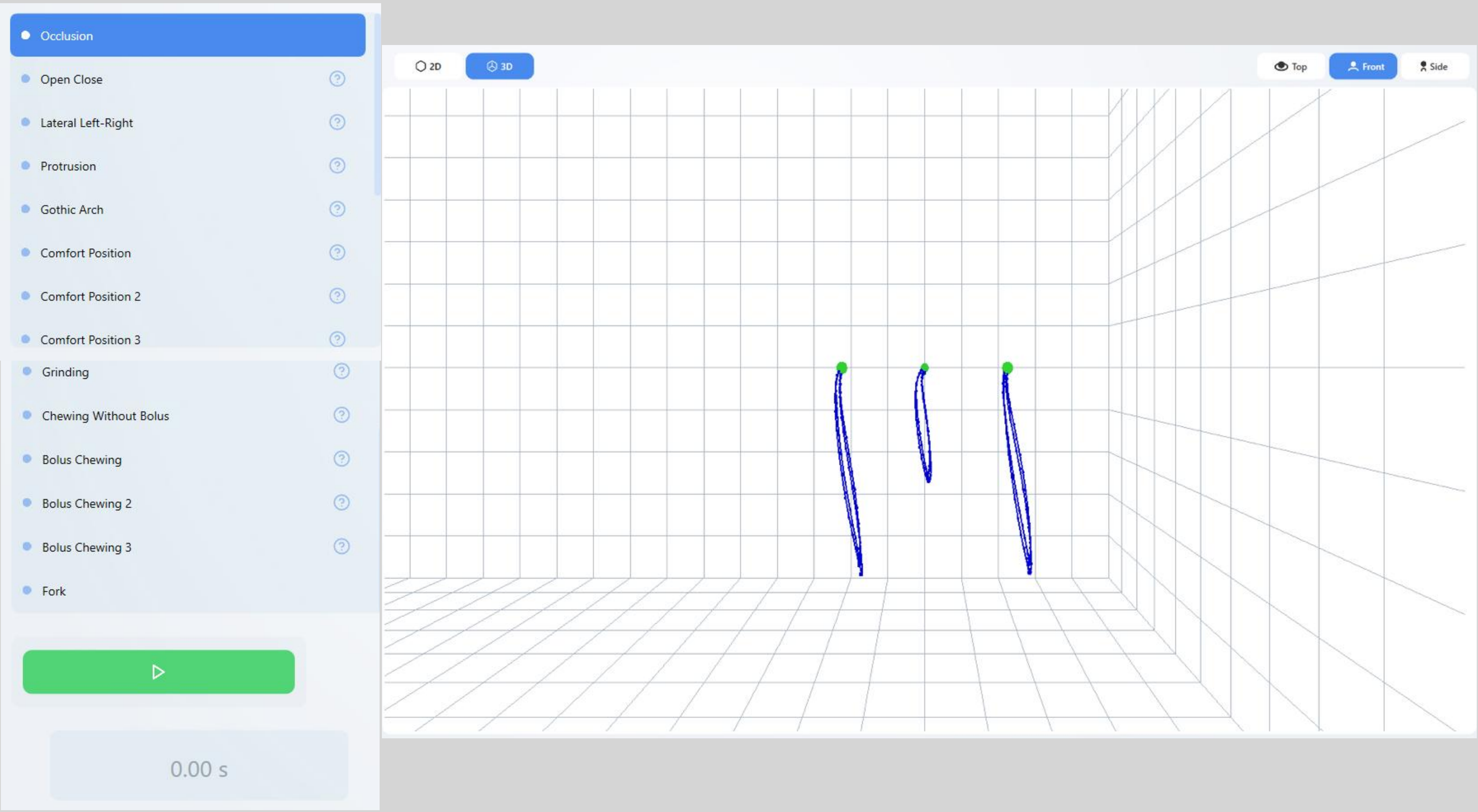
Occlusion
Open Close
Lateral Left-Right
Protrusion
Gothic Arch
Comfort Position
Comfort Position 2
Comfort Position 3
Grinding
Chewing Without Bolus
Bolus Chewing
Bolus Chewing 2
Bolus Chewing 3
Fork
0.00 s
2D
3D
Top
Front
Side



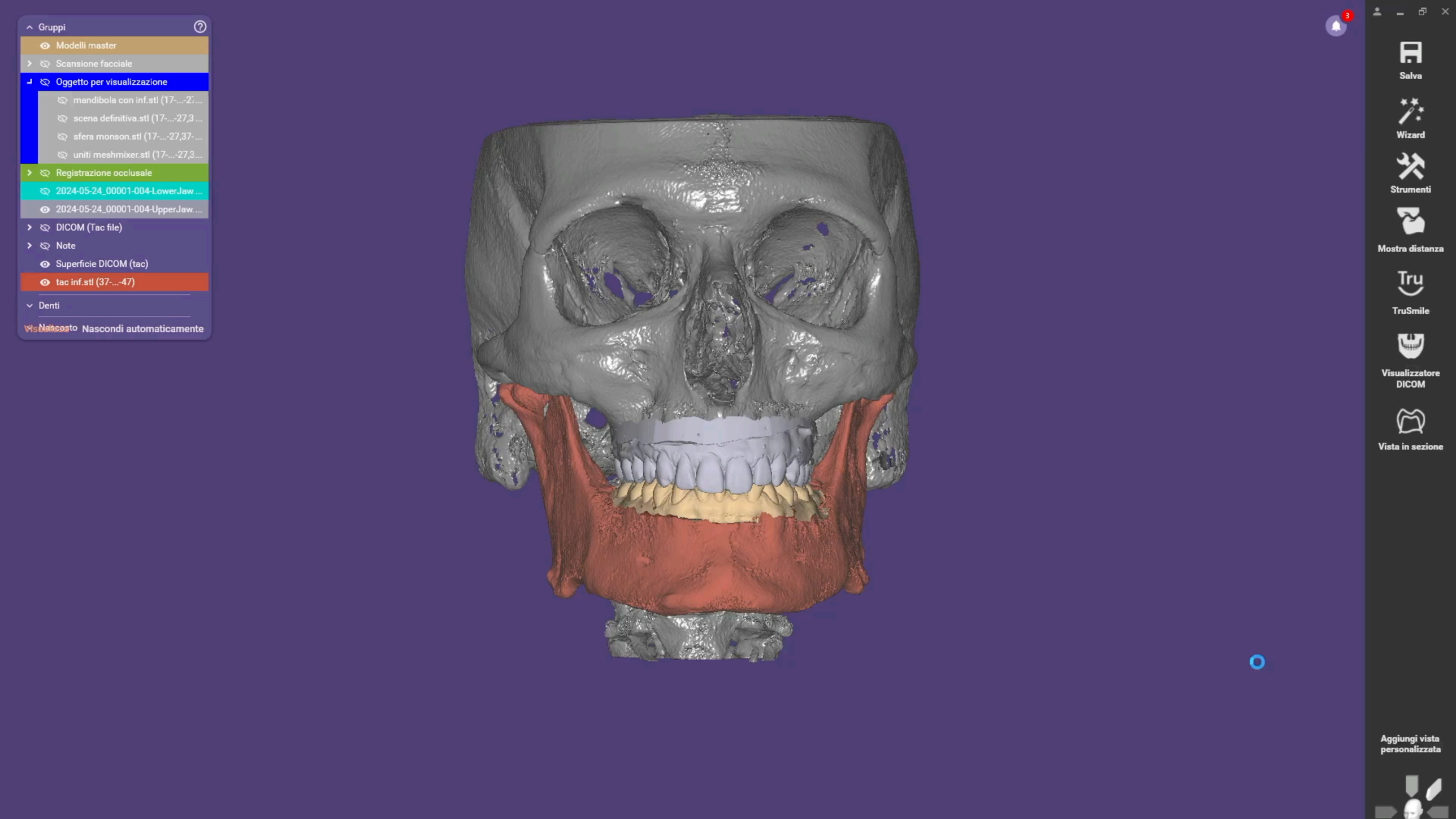
Gruppi
Modelli master
Scansione facciale
Oggetto per visualizzazione
mandibola con inf.stl (17-...-27...
scena definitiva.stl (17-...-27,3 ...
sfera monson.stl (17-...-27,37-...
uniti meshmixer.stl (17-...-27,3...
Registrazione occlusale
2024-05-24_00001-004-LowerJaw ...
2024-05-24_00001-004-UpperJaw....
DICOM (Tac file)
Note
Superficie DICOM (tac)
tac inf.stl (37-...-47)
Denti
Nascosto
Nascondi automaticamente
Salva
Wizard
Strumenti
Mostra distanza
TruSmile
Visualizzatore DICOM
Vista in sezione
Aggiungi vista personalizzata

Monson Sphere

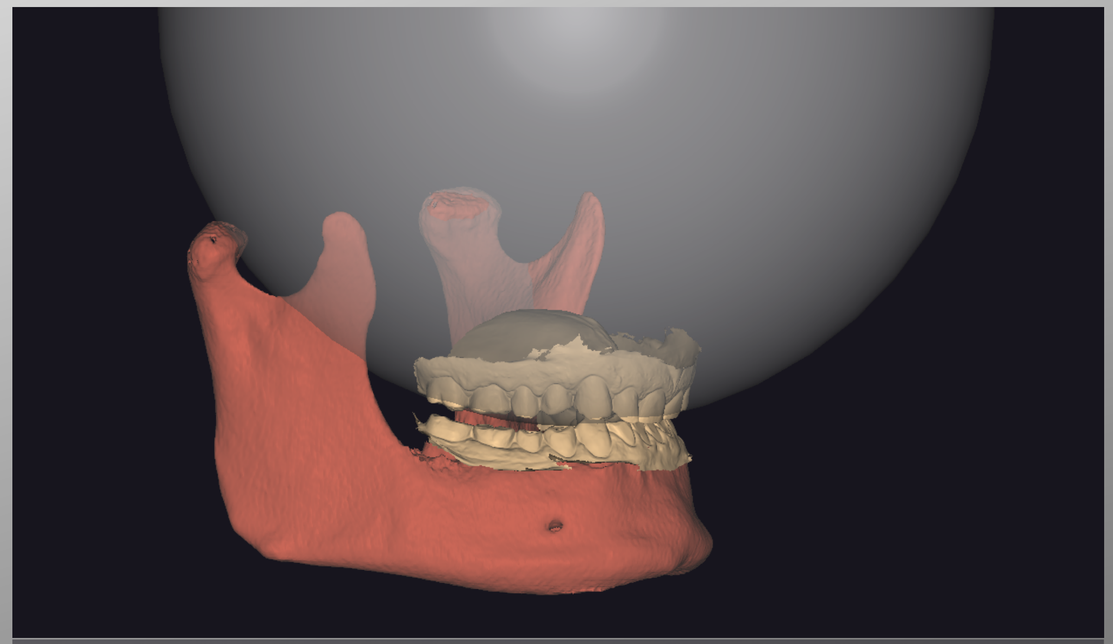

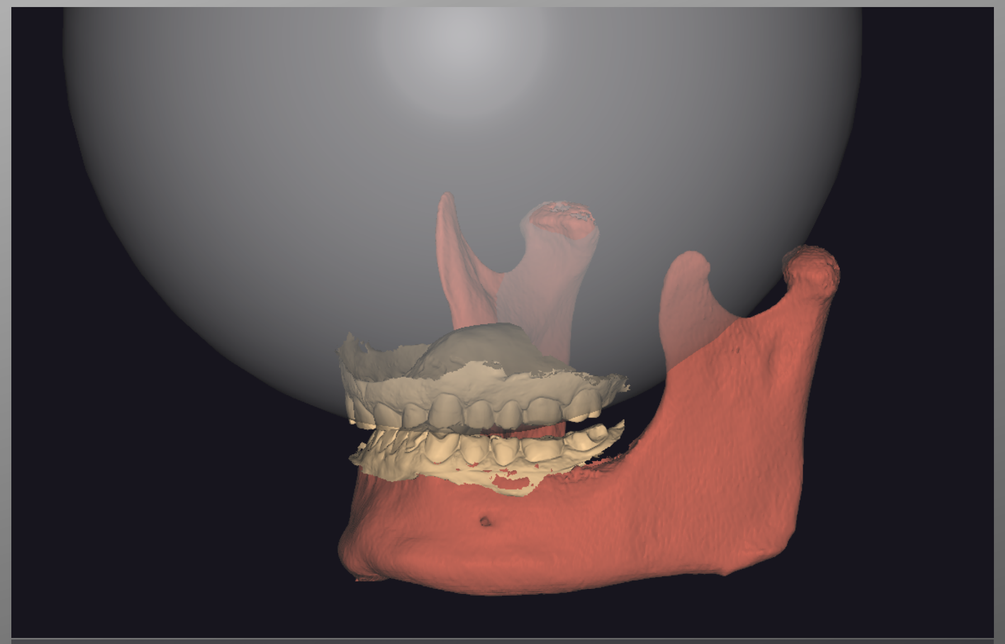

ITAKA







Open Close

KINEJAW exam

Date 25/03/24 30/09/24

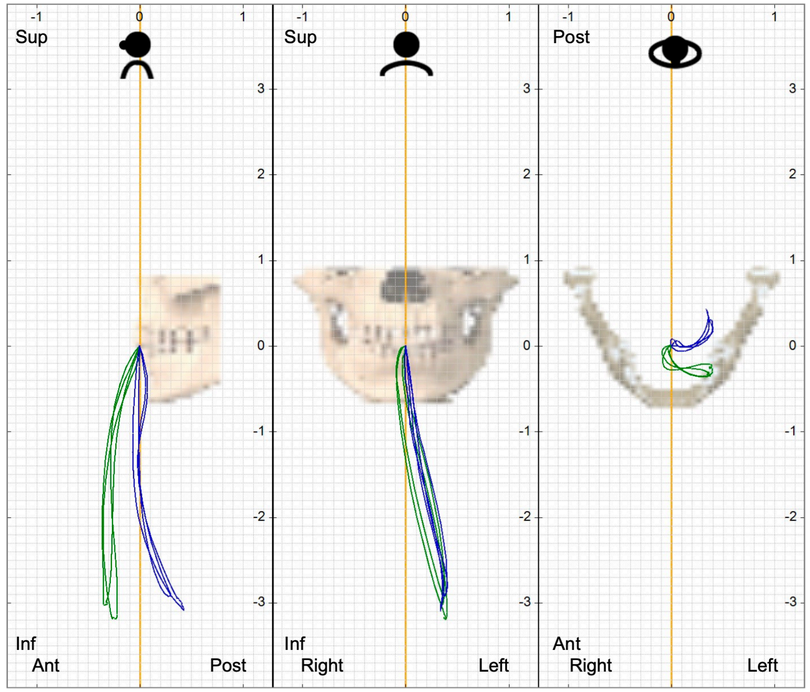

Sagittal			Frontal			Horizontal		
Sup	Inf	Range	Right	Left	Range	Ant	Post	Range
0,00	30,94	30,94	0,04	-4,07	4,11	0,66	-4,31	4,97
0,00	31,93	31,93	0,89	-4,02	4,92	3,61	-0,06	3,67

Protrusion

KINEJAW exam

Date 25/03/24 30/09/24

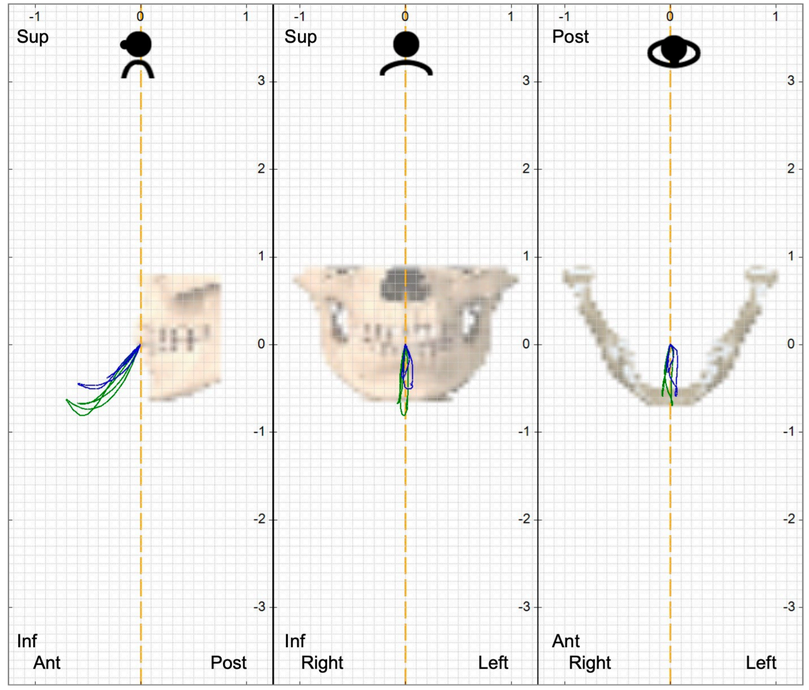

Sagittal			Frontal			Horizontal		
Sup	Inf	Range	Right	Left	Range	Ant	Post	Range
0,00	5,11	5,11	0,31	-0,70	1,02	5,92	0,00	5,92
0,00	8,11	8,11	0,75	-0,28	1,04	7,05	0,00	7,05

Lateral Left-Right

KINEJAW exam

Date 25/03/24 30/09/24

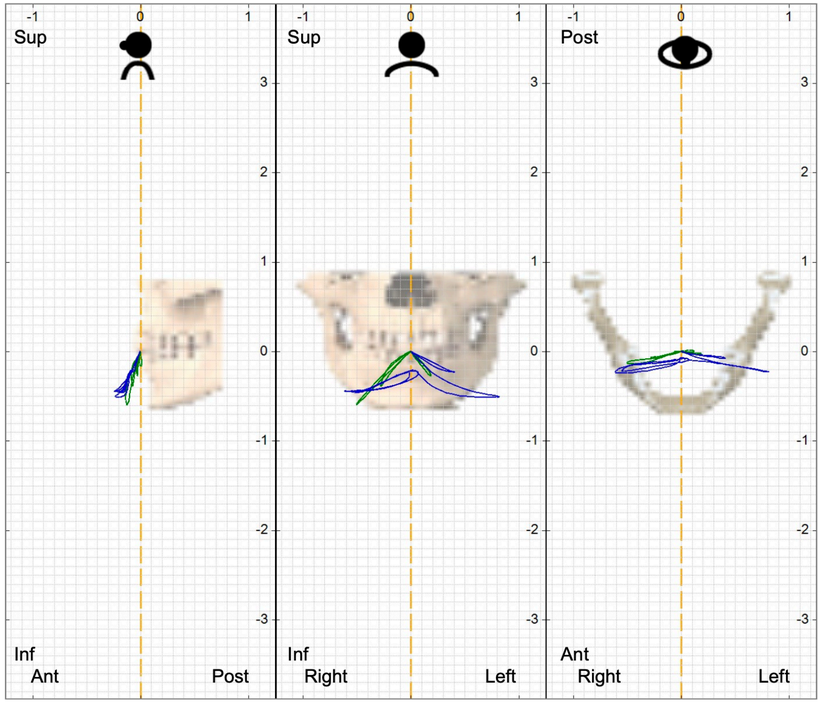

Sagittal			Frontal			Horizontal		
Sup	Inf	Range	Right	Left	Range	Ant	Post	Range
0,00	5,18	5,18	6,11	-8,21	14,32	2,46	0,00	2,46
0,00	5,97	5,97	5,05	-1,89	6,93	1,37	-0,14	1,51

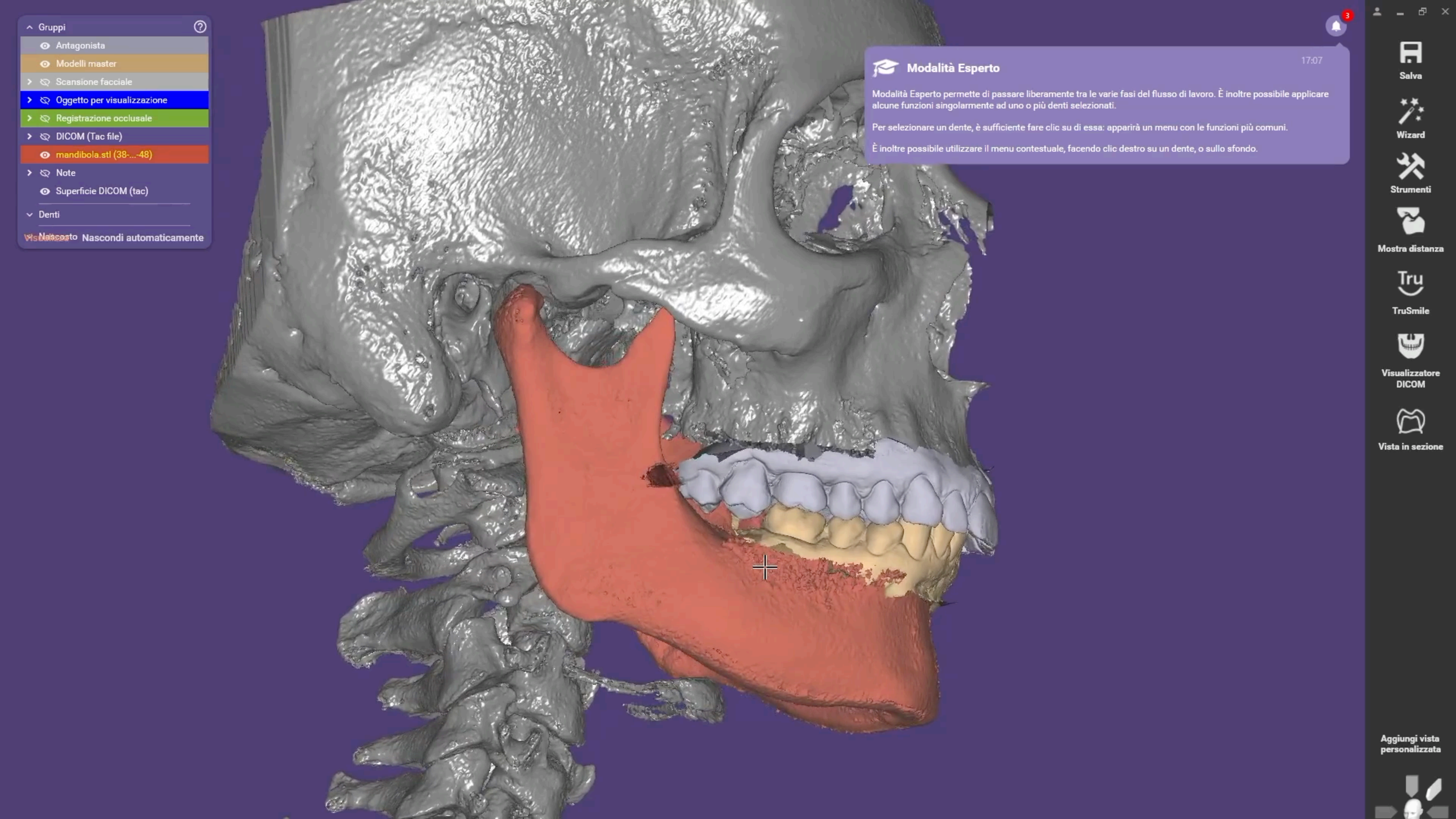
Gruppi
Antagonista
Modelli master
Scansione facciale
Oggetto per visualizzazione
Registrazione occlusale
DICOM (Tac file)
mandibola.stl (38-...-48)
Note
Superficie DICOM (tac)
Denti
Nascosto
Nascondi automaticamente
3
Modalità Esperto
17:07
Modalità Esperto permette di passare liberamente tra le varie fasi del flusso di lavoro. È inoltre possibile applicare alcune funzioni singolarmente ad uno o più denti selezionati.
Per selezionare un dente, è sufficiente fare clic su di essa: apparirà un menu con le funzioni più comuni.
È inoltre possibile utilizzare il menu contestuale, facendo clic destro su un dente, o sullo sfondo.
Salva
Wizard
Strumenti
Mostra distanza
TruSmile
Visualizzatore DICOM
Vista in sezione
Aggiungi vista personalizzata


Rita


Non promettere ciò che non puoi essere sicuro di raggiungere

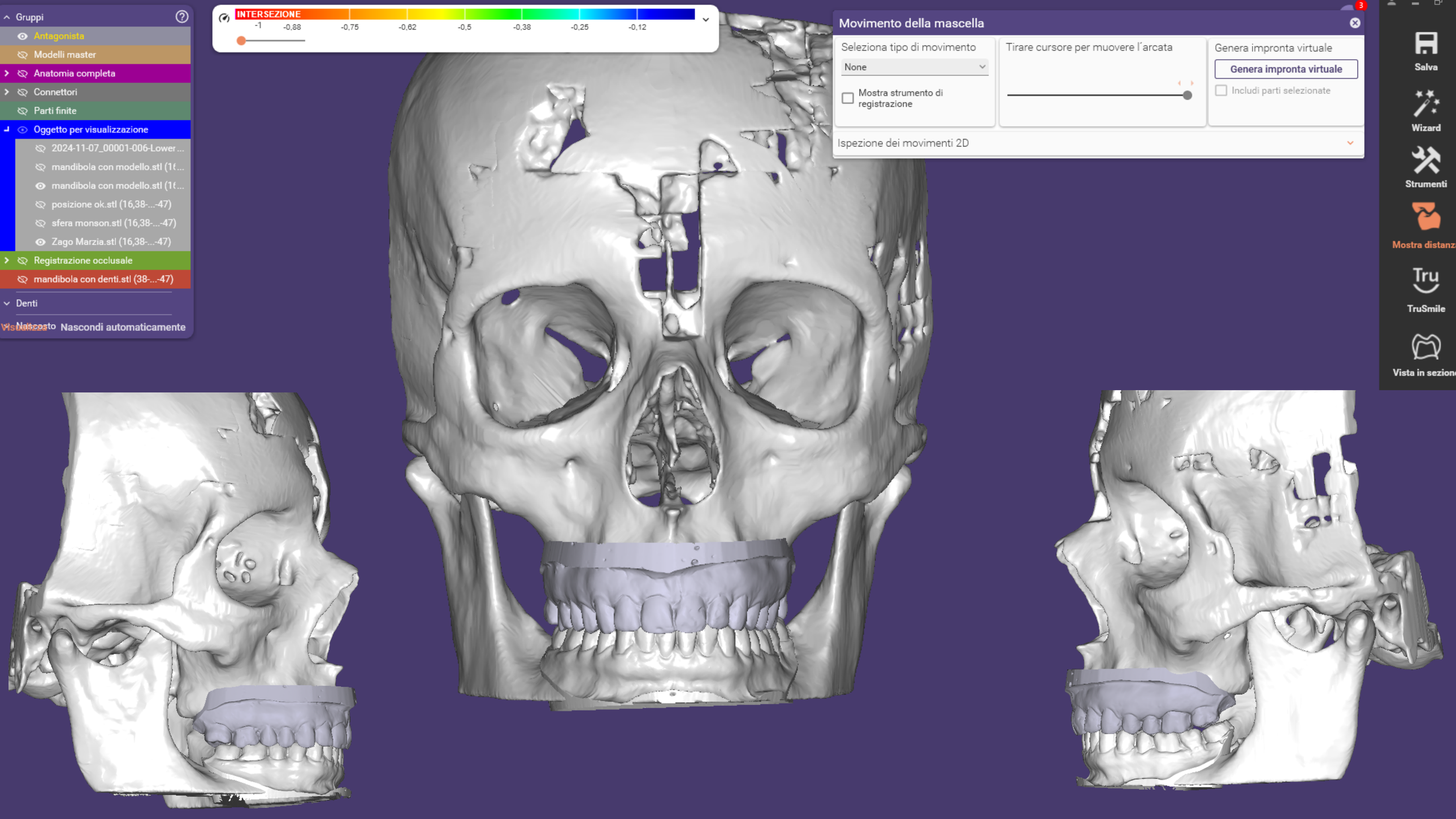
Gruppi
Antagonista
Modelli master
Anatomia completa
Connettori
Parti finite
Oggetto per visualizzazione
2024-11-07_00001-006-Lower ...
mandibola con modello.stl (1(...
mandibola con modello.stl (1(...
posizione ok.stl (16,38-...-47)
sfera monson.stl (16,38-...-47)
Zago Marzia.stl (16,38-...-47)
Registrazione occlusale
mandibola con denti.stl (38-...-47)
Denti
Visibilità
Nascosto
Nascondi automaticamente
INTERSEZIONE
-1
-0,88
-0,75
-0,62
-0,5
-0,38
-0,25
-0,12
Movimento della mascella
Seleziona tipo di movimento
None
Mostra strumento di registrazione
Tirare cursore per muovere l'arcata
Genera impronta virtuale
Genera impronta virtuale
Includi parti selezionate
Ispezione dei movimenti 2D
Salva
Wizard
Strumenti
Mostra distanz
Tru
TruSmile
Vista in sezione

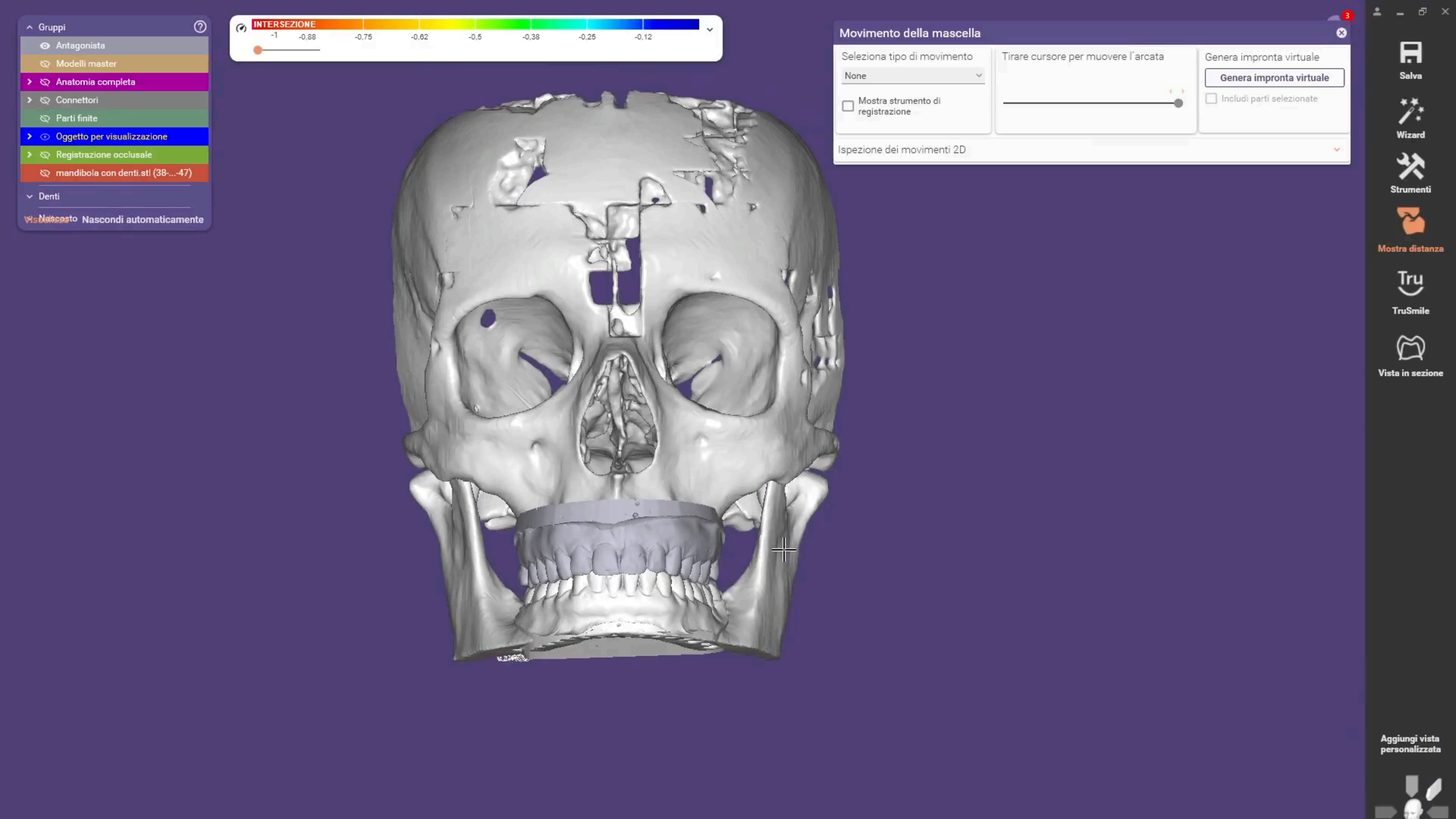
Gruppi
Antagonista
Modelli master
Anatomia completa
Connettori
Parti finite
Oggetto per visualizzazione
Registrazione occlusale
mandibola con denti.stl (38-...-47)
Denti
Nascosto
Nascondi automaticamente
INTERSEZIONE
-1
-0,88
-0,75
-0,62
-0,5
-0,38
-0,25
-0,12
Movimento della mascella
Seleziona tipo di movimento
None
Mostra strumento di registrazione
Tirare cursore per muovere l'arcata
Genera impronta virtuale
Genera impronta virtuale
Includi parti selezionate
Ispezione dei movimenti 2D
Salva
Wizard
Strumenti
Mostra distanza
TruSmile
Vista in sezione
Aggiungi vista personalizzata

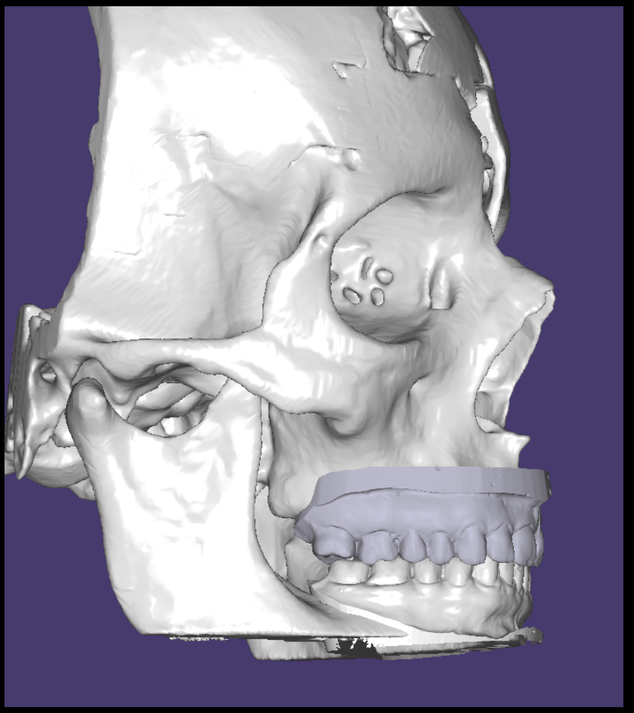

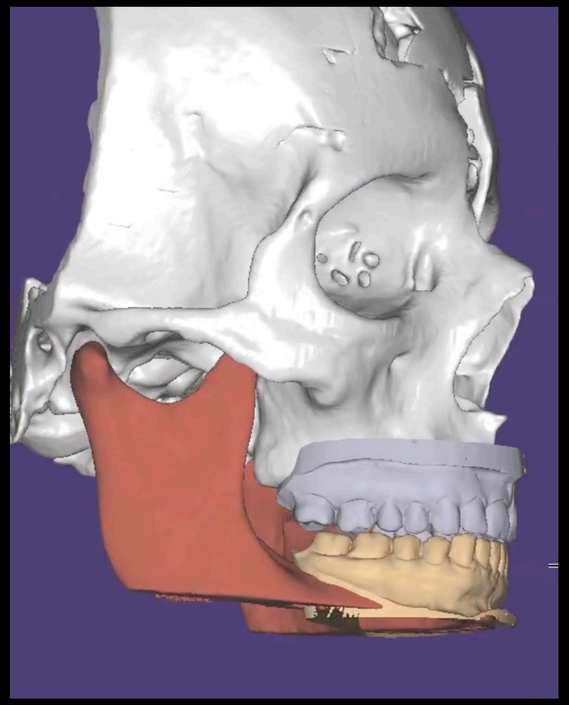

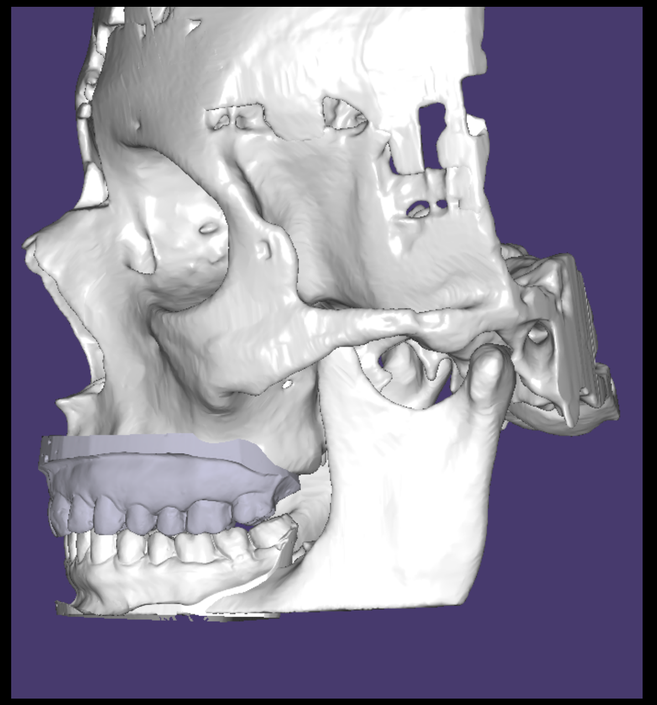

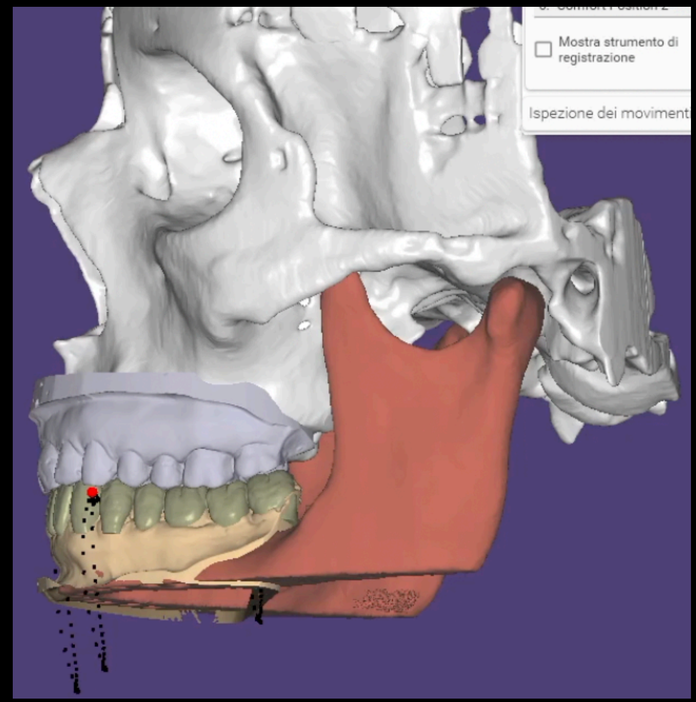
Mostra strumento di registrazione
Ispezione dei moviment

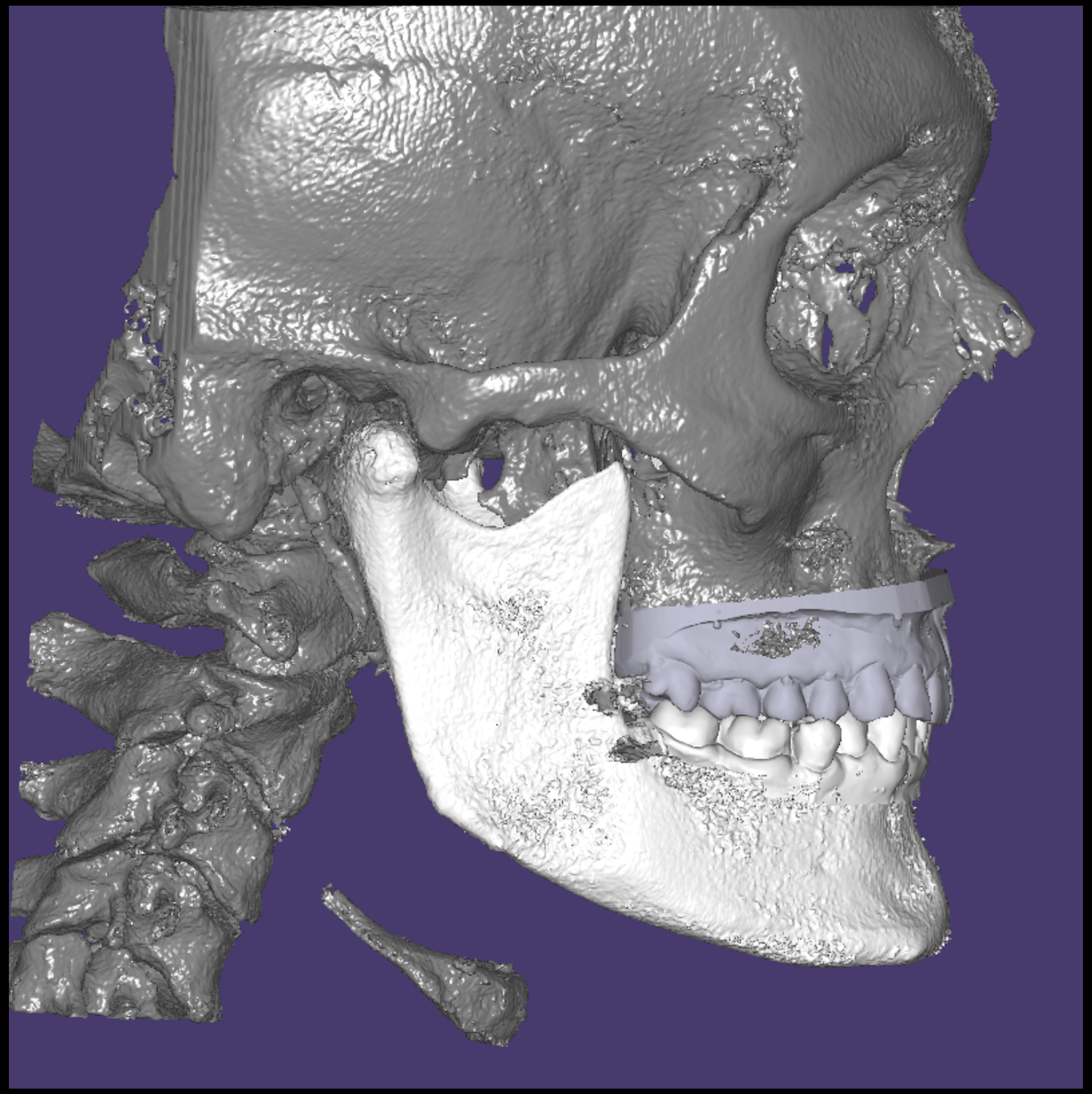

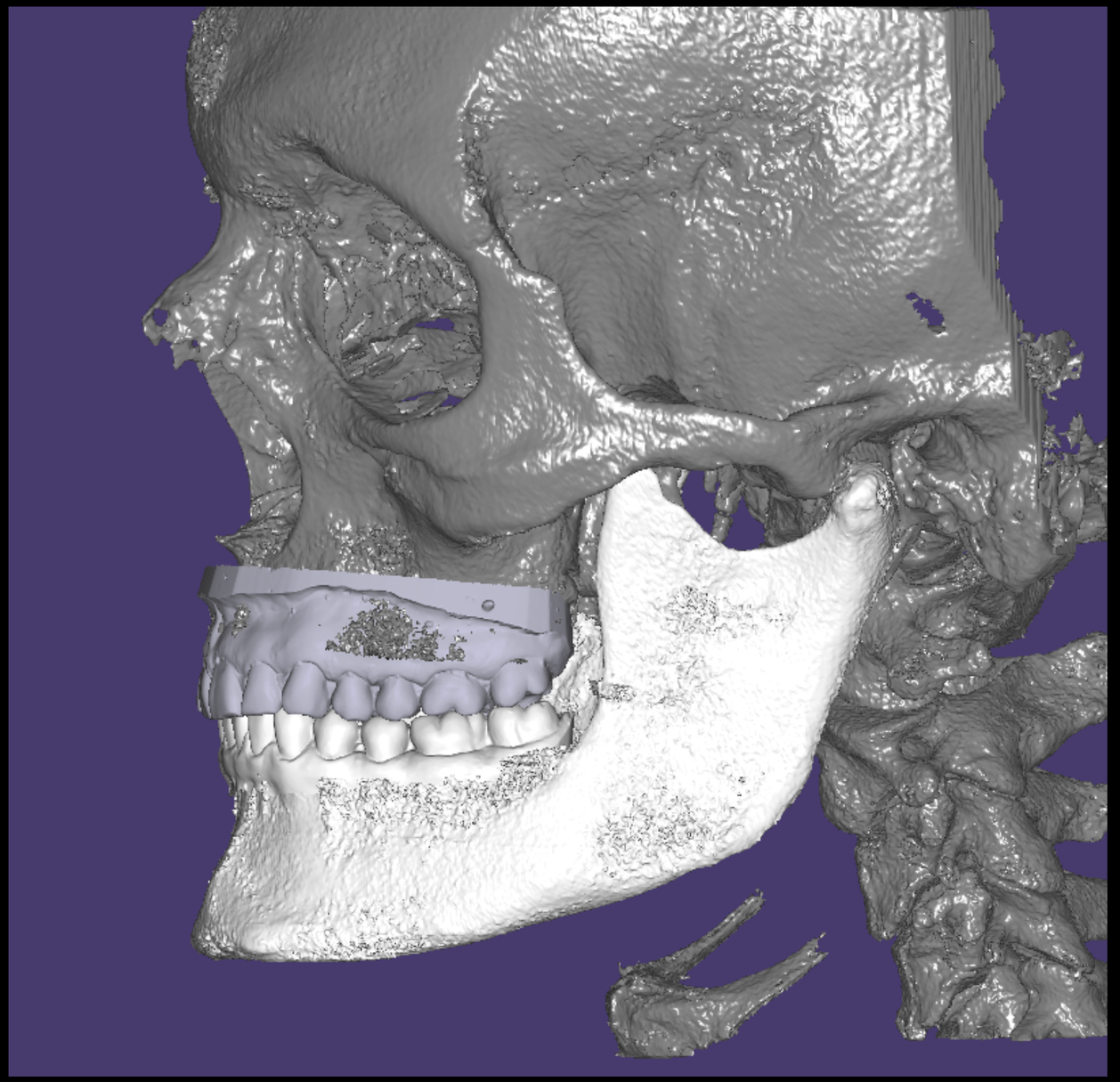

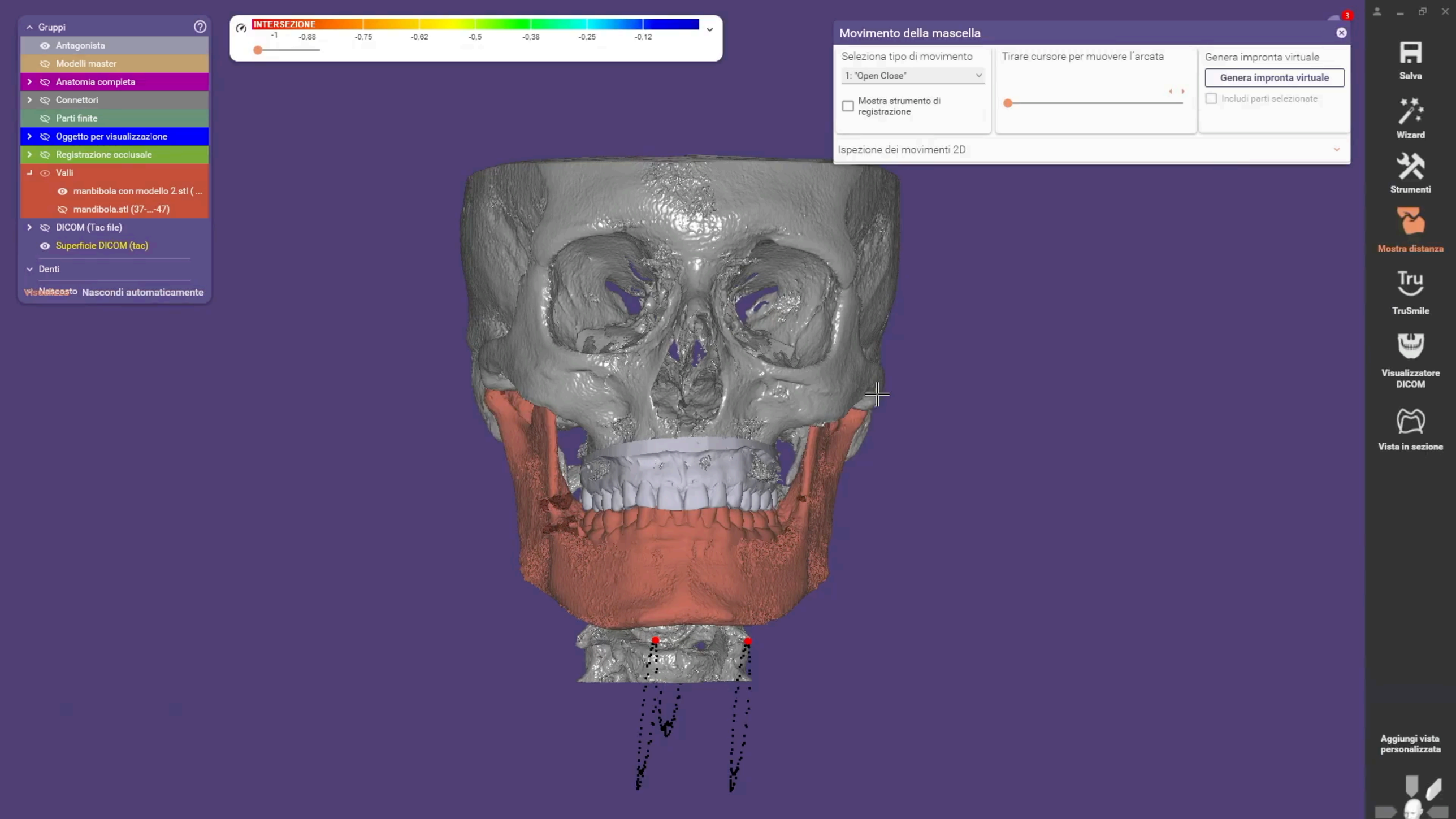
Gruppi
Antagonista
Modelli master
Anatomia completa
Connettori
Parti finite
Oggetto per visualizzazione
Registrazione occlusale
Valli
manbibola con modello 2.stl (...
mandibola.stl (37-...-47)
DICOM (Tac file)
Superficie DICOM (tac)
Denti
Nascosto
Nascondi automaticamente
INTERSEZIONE
-1
-0,88
-0,75
-0,62
-0,5
-0,38
-0,25
-0,12
Movimento della mascella
Seleziona tipo di movimento
1: "Open Close"
Mostra strumento di registrazione
Tirare cursore per muovere l´arcata
Genera impronta virtuale
Genera impronta virtuale
Includi parti selezionate
Ispezione dei movimenti 2D
Salva
Wizard
Strumenti
Mostra distanza
TruSmile
Visualizzatore DICOM
Vista in sezione
Aggiungi vista personalizzata

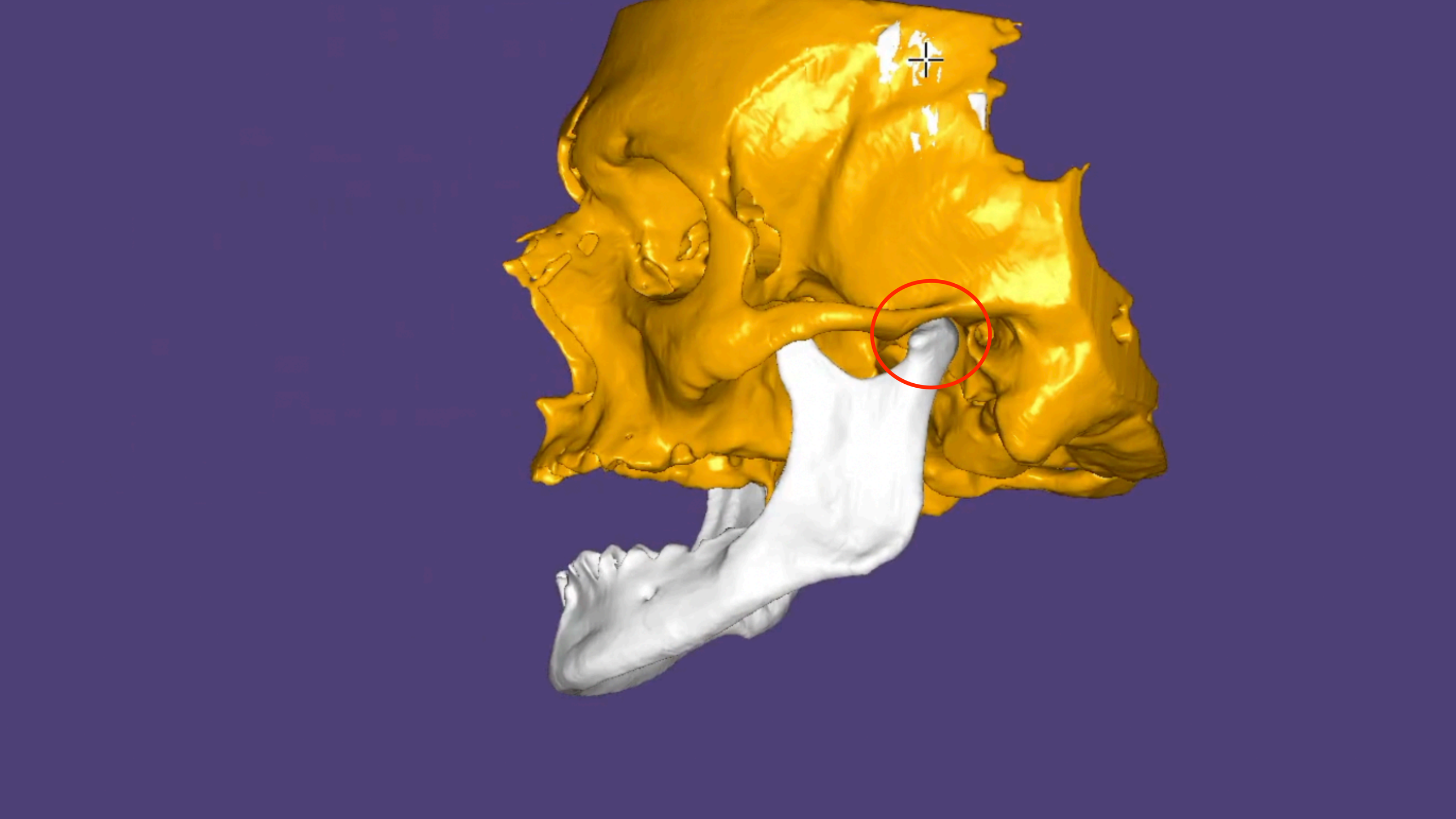

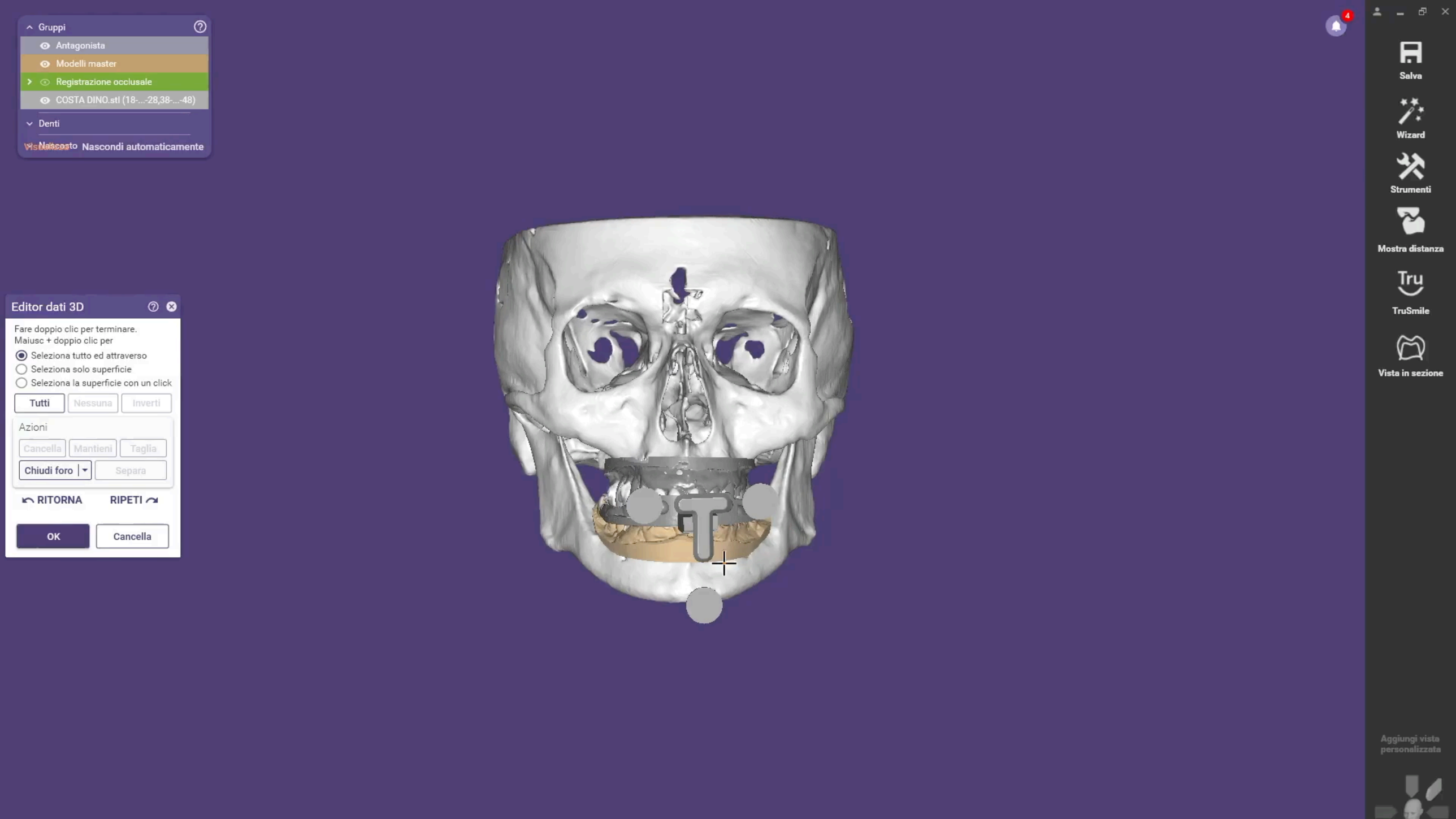
Gruppi
Antagonista
Modelli master
Registrazione occlusale
COSTA DINO.stl (18-...-28,38-...-48)
Denti
Nascosto
Nascondi automaticamente
Editor dati 3D
Fare doppio clic per terminare.
Maiusc + doppio clic per
Seleziona tutto ed attraverso
Seleziona solo superficie
Seleziona la superficie con un click
Tutti
Nessuna
Inverti
Azioni
Cancella
Mantieni
Taglia
Chiudi foro
Separa
RITORNA
RIPETI
OK
Cancella
Salva
Wizard
Strumenti
Mostra distanza
TruSmile
Vista in sezione
Aggiungi vista personalizzata




















RSF



































Nel rispetto assoluto dei tessuti duri e molli





















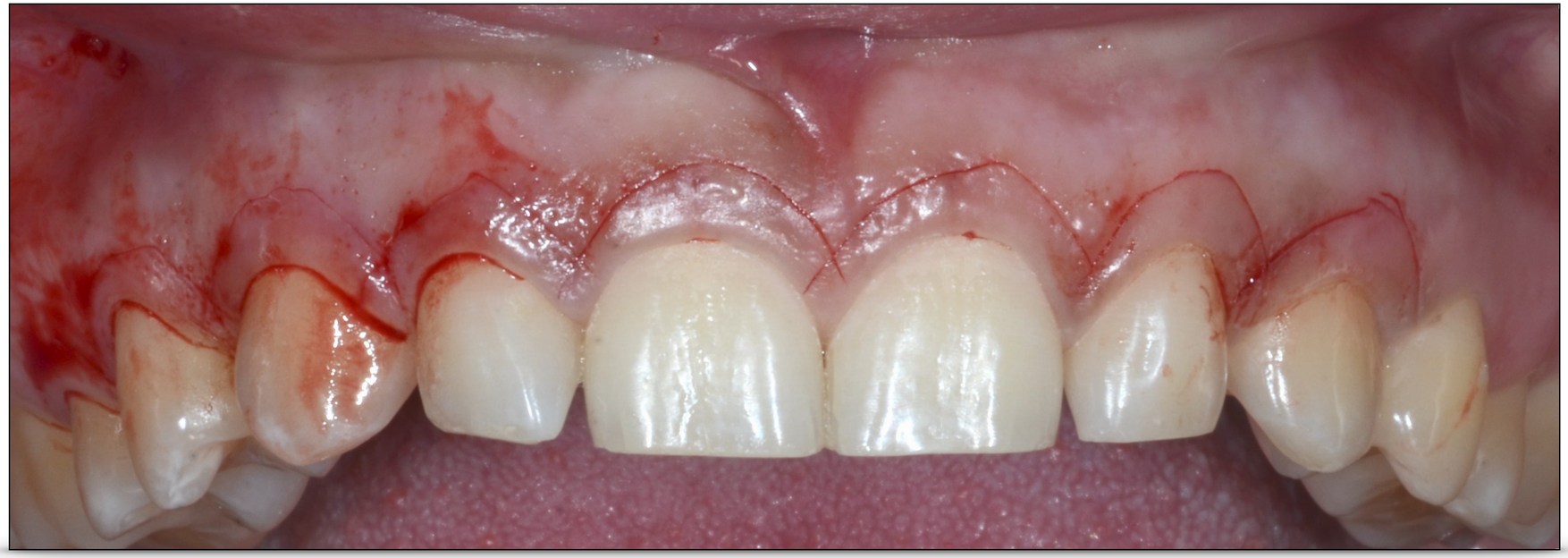





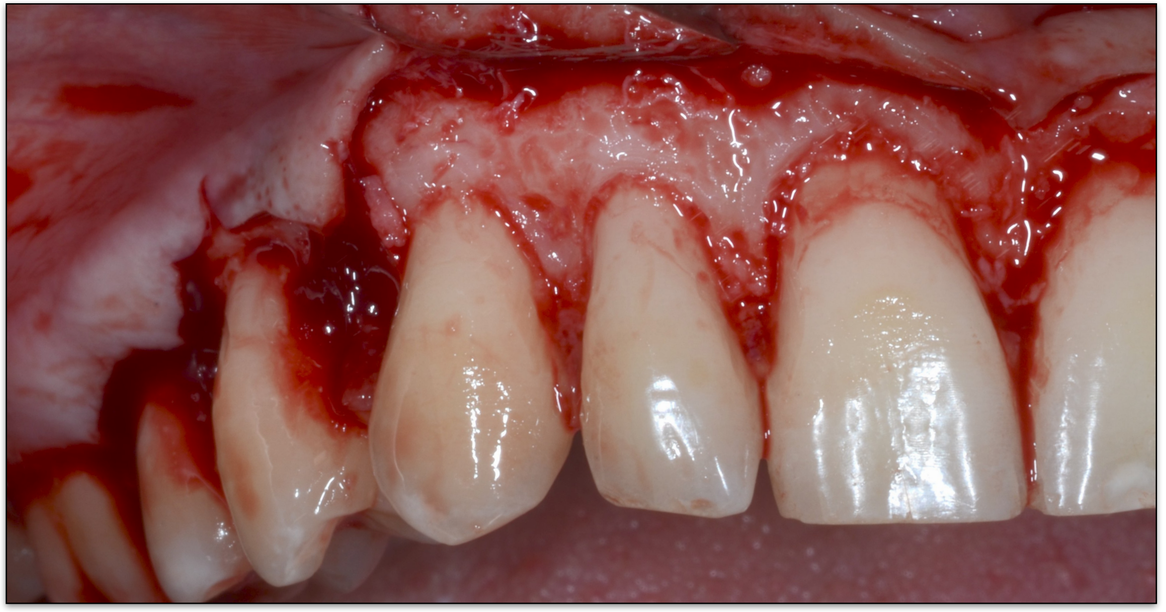










Servono questi sistemi
in tutti i casi?

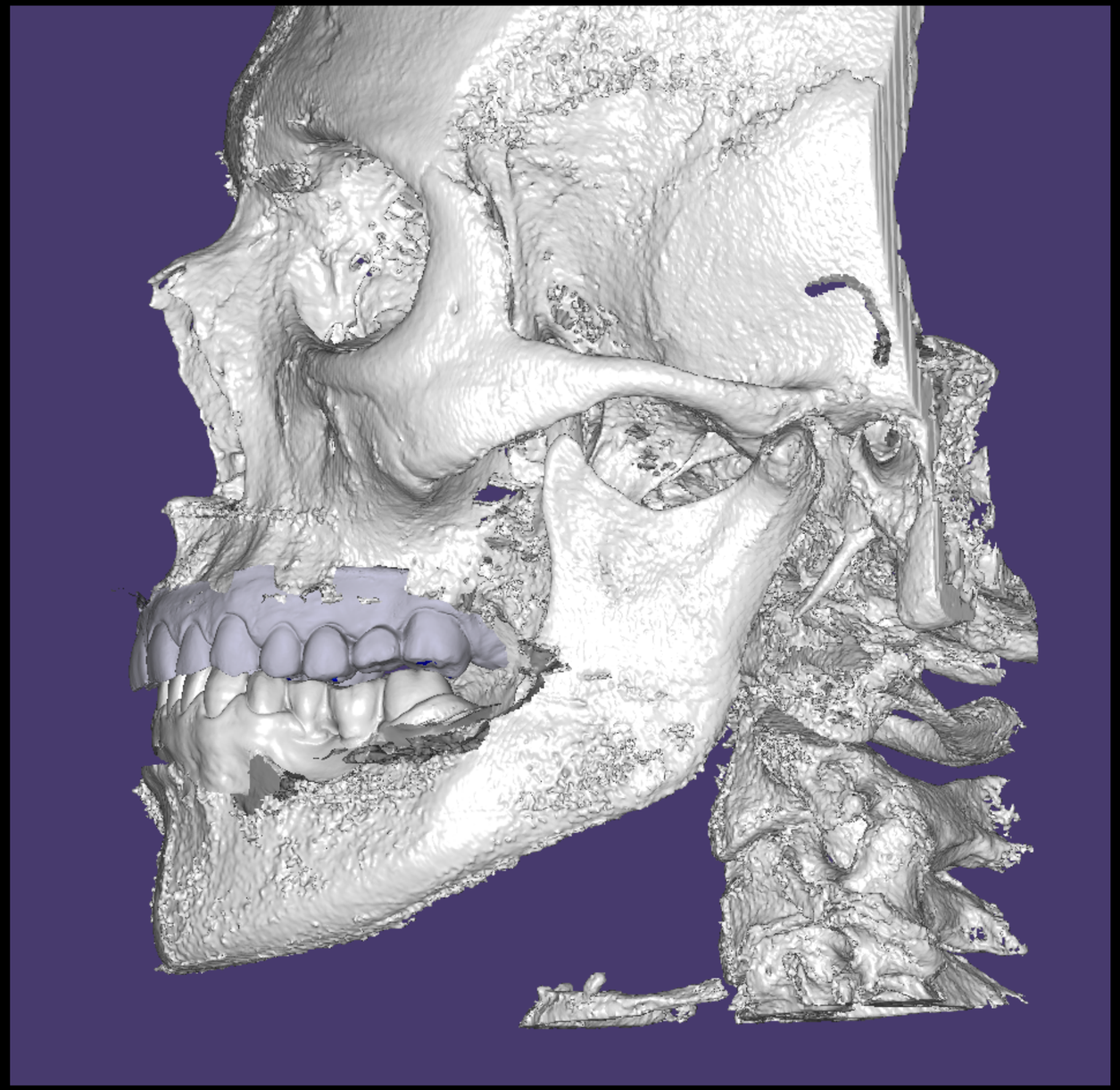

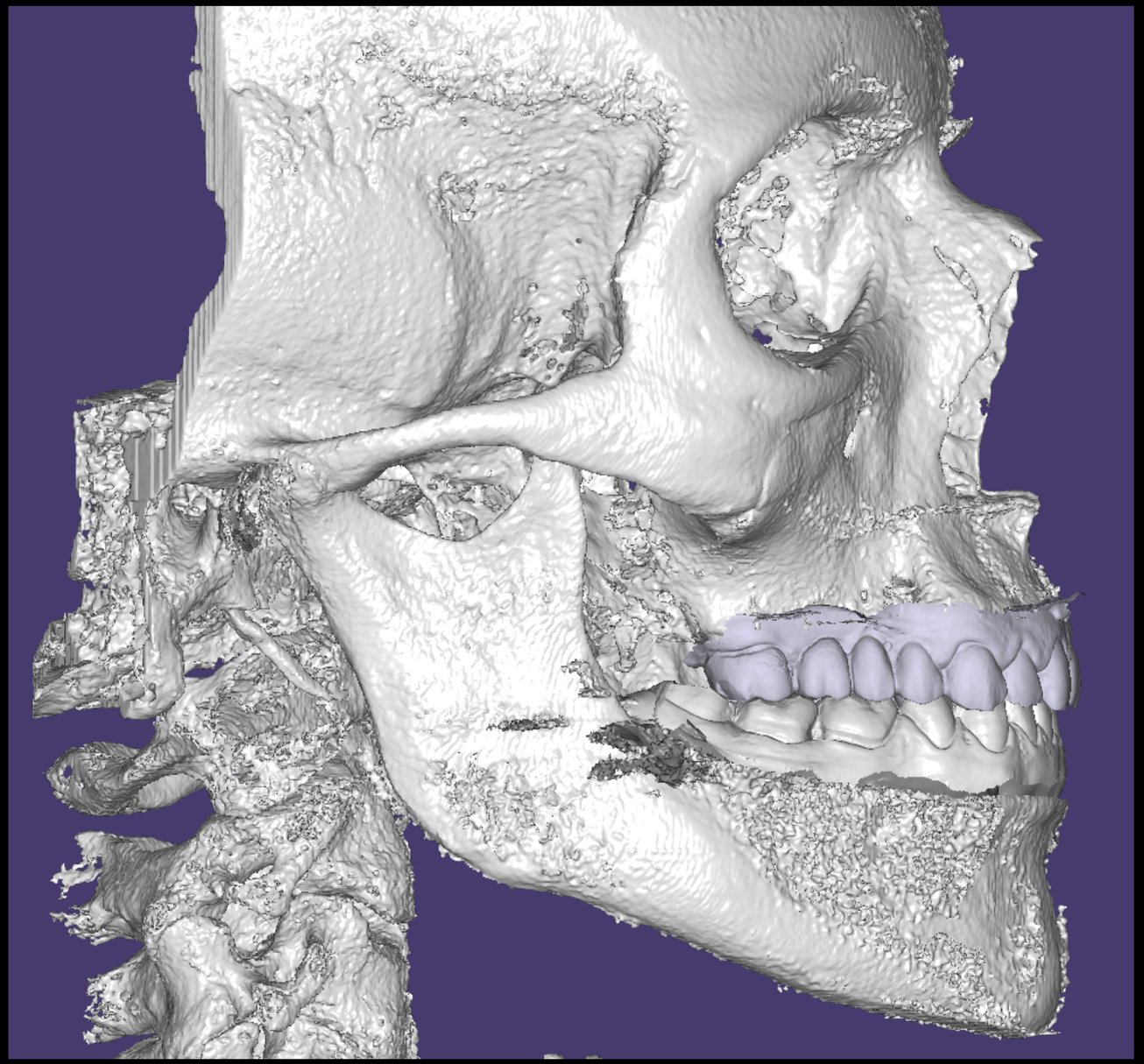

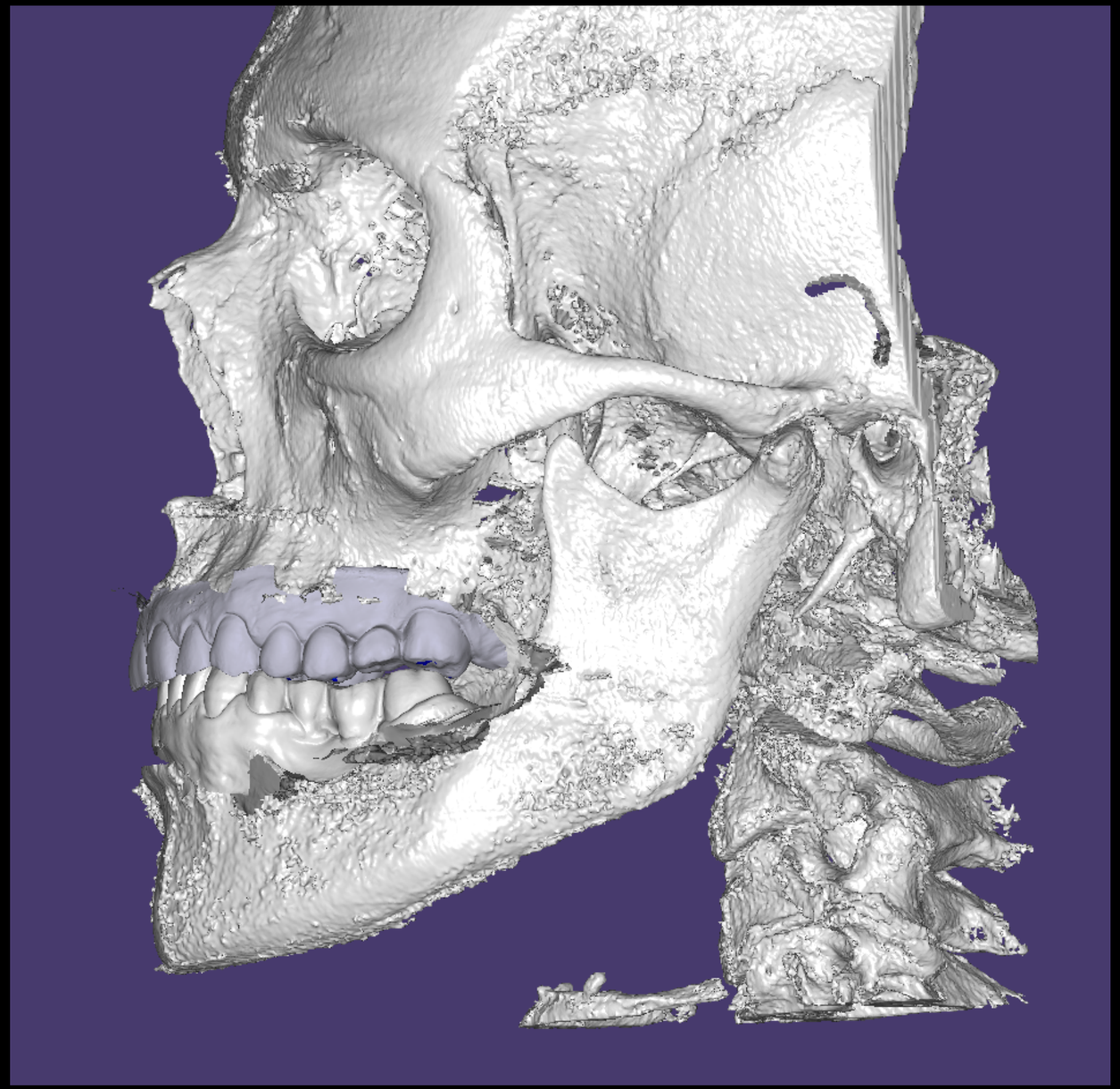

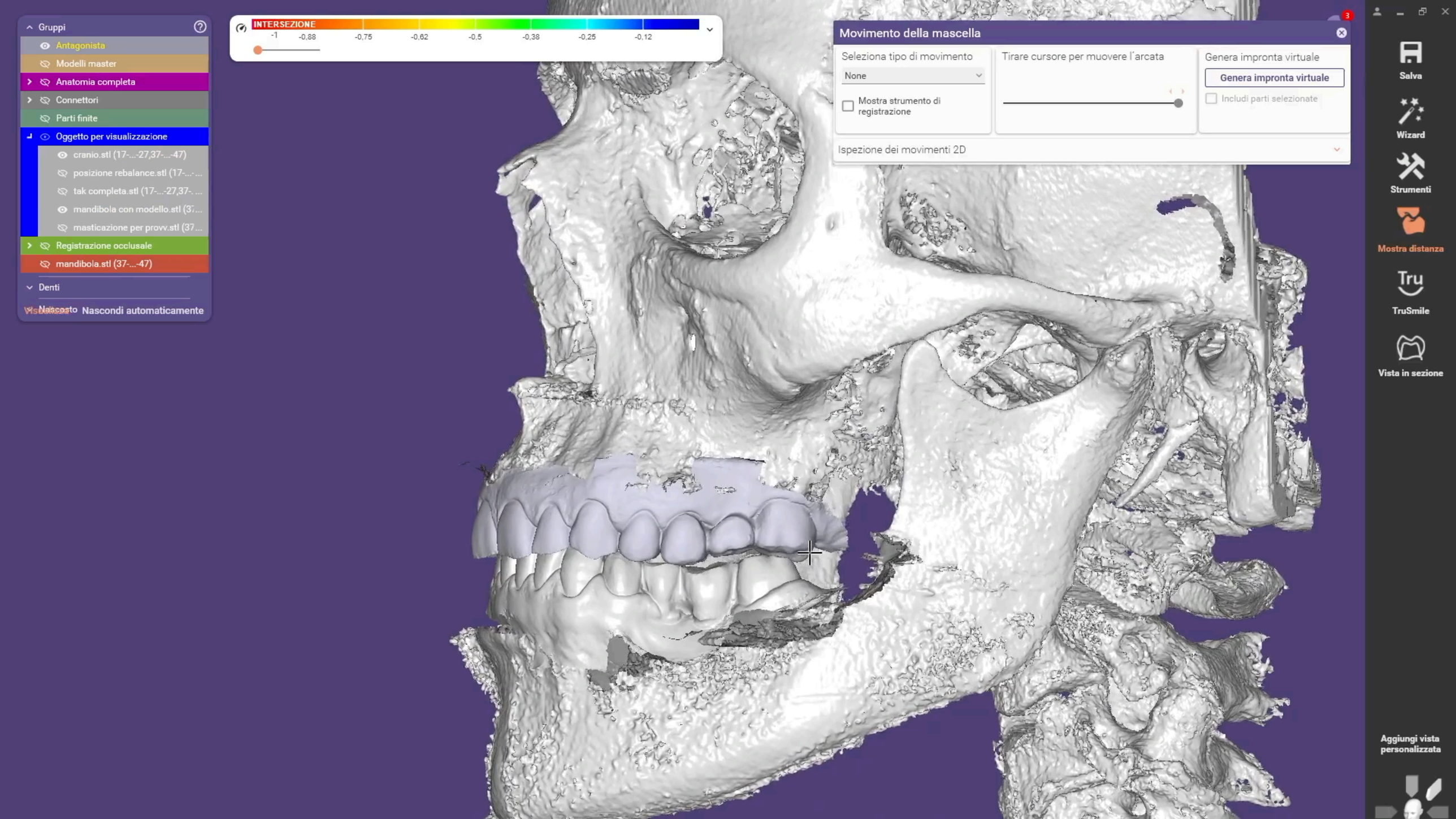
Gruppi
Antagonista
Modelli master
Anatomia completa
Connettori
Parti finite
Oggetto per visualizzazione
cranio.stl (17-...-27,37-...-47)
posizione rebalance.stl (17-...-...
tak completa.stl (17-...-27,37-...
mandibola con modello.stl (37...
masticazione per provv.stl (37...
Registrazione occlusale
mandibola.stl (37-...-47)
Denti
Nascosto
Nascondi automaticamente
INTERSEZIONE
-1
-0,88
-0,75
-0,62
-0,5
-0,38
-0,25
-0,12
Movimento della mascella
Seleziona tipo di movimento
None
Mostra strumento di registrazione
Tirare cursore per muovere l'arcata
Genera impronta virtuale
Genera impronta virtuale
Includi parti selezionate
Ispezione dei movimenti 2D
Salva
Wizard
Strumenti
Mostra distanza
TruSmile
Vista in sezione
Aggiungi vista personalizzata


Ma cosa posso osservare ?

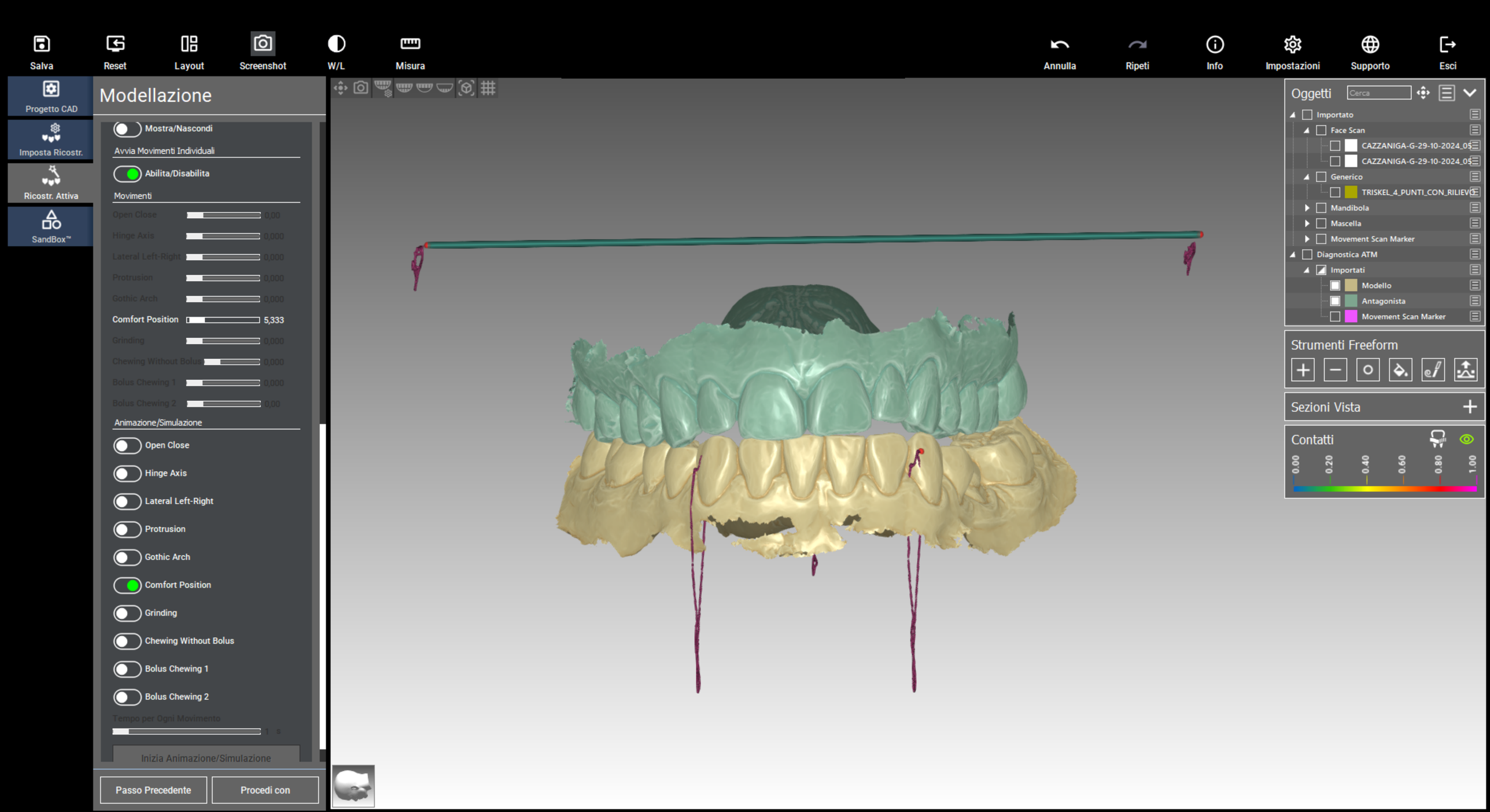
Salva
Reset
Layout
Screenshot
W/L
Misura
Annulla
Ripeti
Info
Impostazioni
Supporto
Esci
Progetto CAD
Imposta Ricostr.
Ricostr. Attiva
SandBox™
Modellazione
Mostra/Nascondi
Avvia Movimenti Individuali
Abilita/Disabilita
Movimenti
Open Close 0,00
Hinge Axis 0,000
Lateral Left-Right 0,000
Protrusion 0,000
Gothic Arch 0,000
Comfort Position 5,333
Grinding 0,000
Chewing Without Bolus 0,000
Bolus Chewing 1 0,000
Bolus Chewing 2 0,00
Animazione/Simulazione
Open Close
Hinge Axis
Lateral Left-Right
Protrusion
Gothic Arch
Comfort Position
Grinding
Chewing Without Bolus
Bolus Chewing 1
Bolus Chewing 2
Tempo per Ogni Movimento
Inizia Animazione/Simulazione
Passo Precedente
Procedi con
Oggetti
Cerca
Importato
Face Scan
CAZZANIGA-G-29-10-2024_05
CAZZANIGA-G-29-10-2024_05
Generico
TRISKEL_4_PUNTI_CON_RILIEVO
Mandibola
Mascella
Movement Scan Marker
Diagnostica ATM
Importati
Modello
Antagonista
Movement Scan Marker
Strumenti Freeform
Sezioni Vista
Contatti
0.00
0.20
0.40
0.60
0.80
1.00

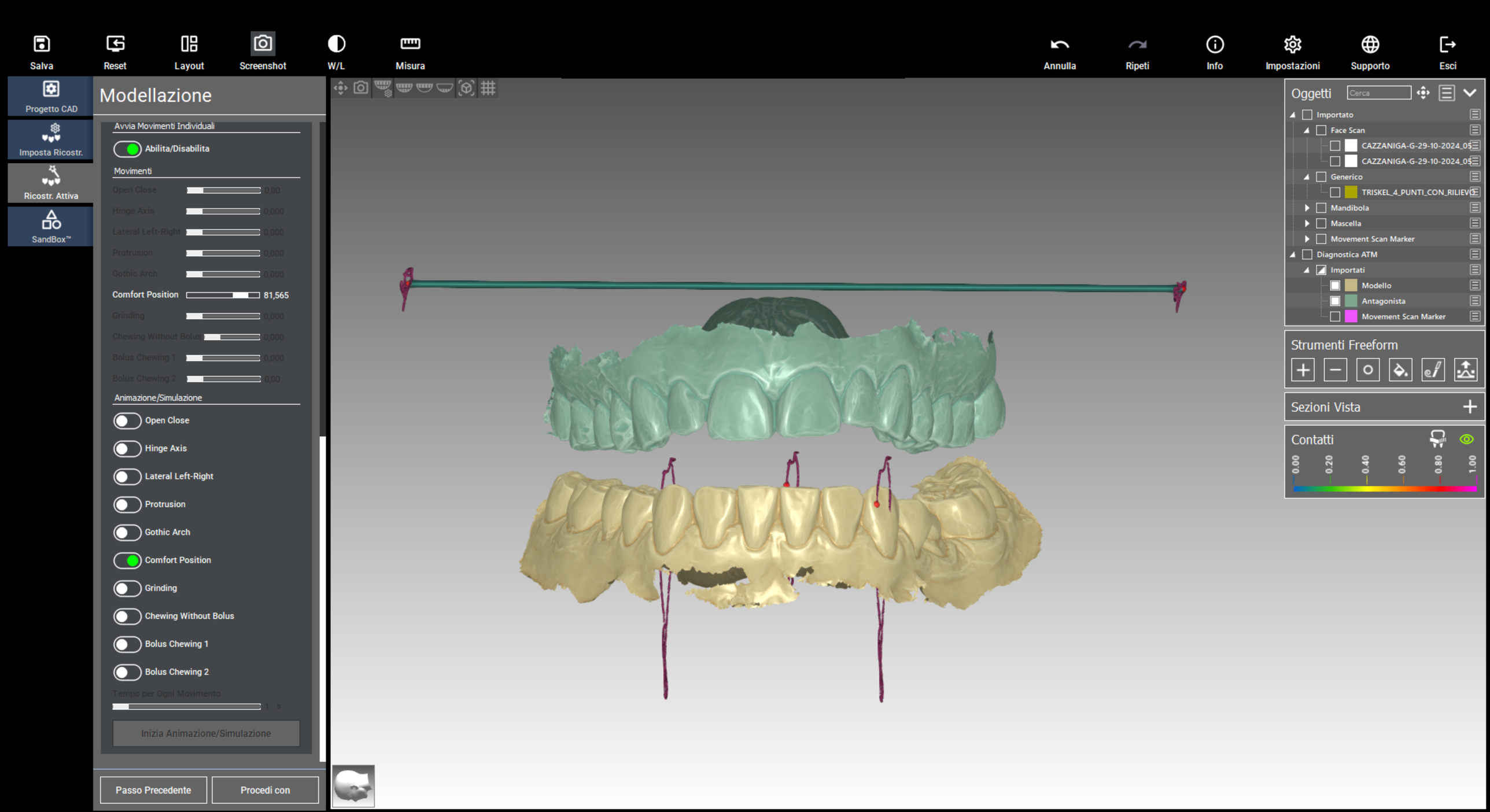
Salva
Reset
Layout
Screenshot
W/L
Misura
Annulla
Ripeti
Info
Impostazioni
Supporto
Esci
Progetto CAD
Imposta Ricostr.
Ricostr. Attiva
SandBox™
Modellazione
Avvia Movimenti Individuali
Abilita/Disabilita
Movimenti
Open Close
Hinge Axis
Lateral Left-Right
Protrusion
Gothic Arch
Comfort Position
81,565
Grinding
Chewing Without Bolus
Bolus Chewing 1
Bolus Chewing 2
Animazione/Simulazione
Open Close
Hinge Axis
Lateral Left-Right
Protrusion
Gothic Arch
Comfort Position
Grinding
Chewing Without Bolus
Bolus Chewing 1
Bolus Chewing 2
Tempo per Ogni Movimento
Inizia Animazione/Simulazione
Passo Precedente
Procedi con
Oggetti
Cerca
Importato
Face Scan
CAZZANIGA-G-29-10-2024_05
CAZZANIGA-G-29-10-2024_05
Generico
TRISKEL_4_PUNTI_CON_RILIEVO
Mandibola
Mascella
Movement Scan Marker
Diagnostica ATM
Importati
Modello
Antagonista
Movement Scan Marker
Strumenti Freeform
Sezioni Vista
Contatti
0.00
0.20
0.40
0.60
0.80
1.00

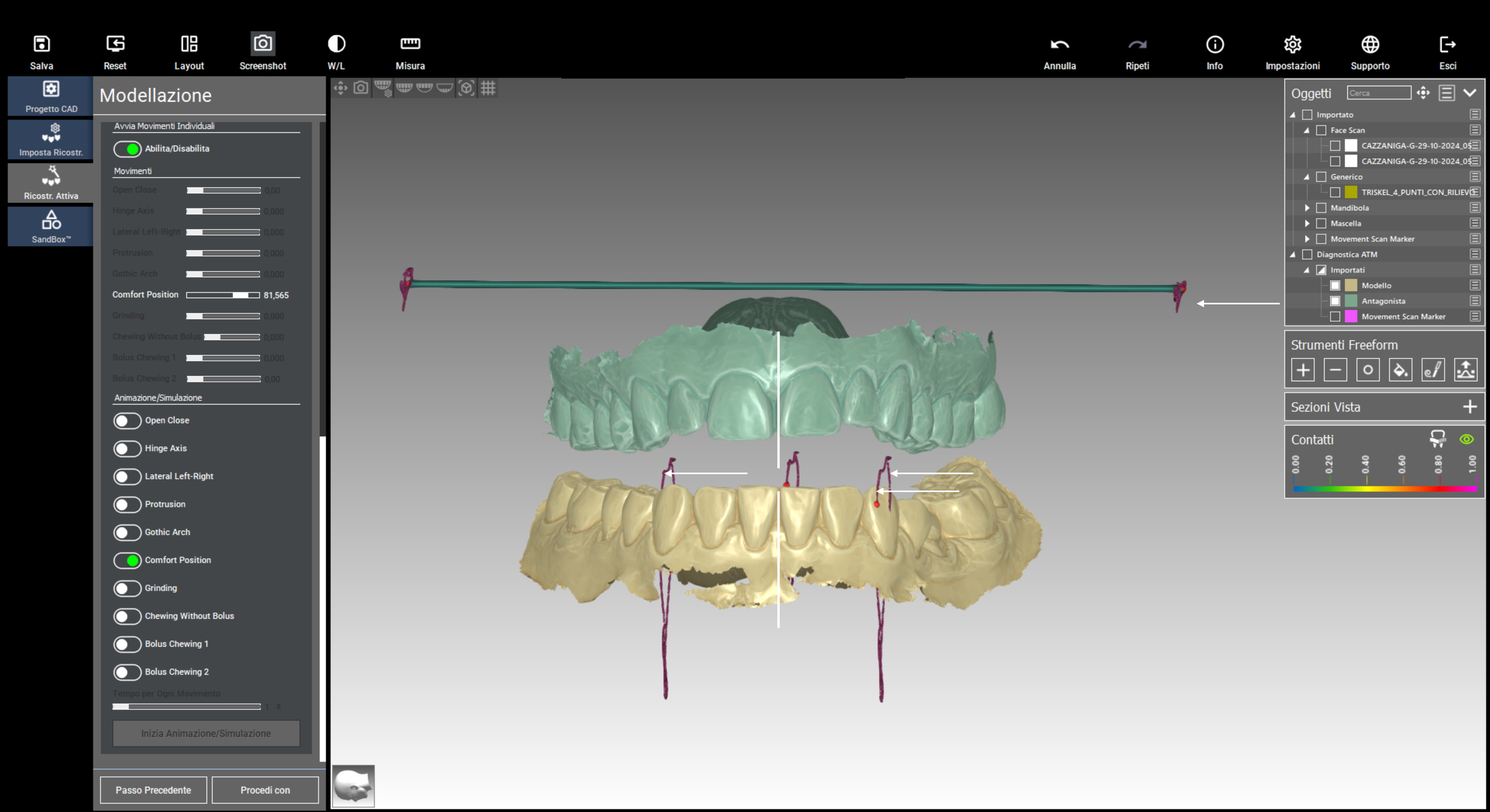
Salva
Reset
Layout
Screenshot
W/L
Misura
Annulla
Ripeti
Info
Impostazioni
Supporto
Esci
Progetto CAD
Imposta Ricostr.
Ricostr. Attiva
SandBox™
Modellazione
Avvia Movimenti Individuali
Abilita/Disabilita
Movimenti
Open Close
Hinge Axis
Lateral Left-Right
Protrusion
Gothic Arch
Comfort Position
81,565
Grinding
Chewing Without Bolus
Bolus Chewing 1
Bolus Chewing 2
Animazione/Simulazione
Open Close
Hinge Axis
Lateral Left-Right
Protrusion
Gothic Arch
Comfort Position
Grinding
Chewing Without Bolus
Bolus Chewing 1
Bolus Chewing 2
Tempo per Ogni Movimento
Inizia Animazione/Simulazione
Passo Precedente
Procedi con
Oggetti
Cerca
Importato
Face Scan
CAZZANIGA-G-29-10-2024_05
CAZZANIGA-G-29-10-2024_05
Generico
TRISKEL_4_PUNTI_CON_RILIEVO
Mandibola
Mascella
Movement Scan Marker
Diagnostica ATM
Importati
Modello
Antagonista
Movement Scan Marker
Strumenti Freeform
Sezioni Vista
Contatti
0.00
0.20
0.40
0.60
0.80
1.00

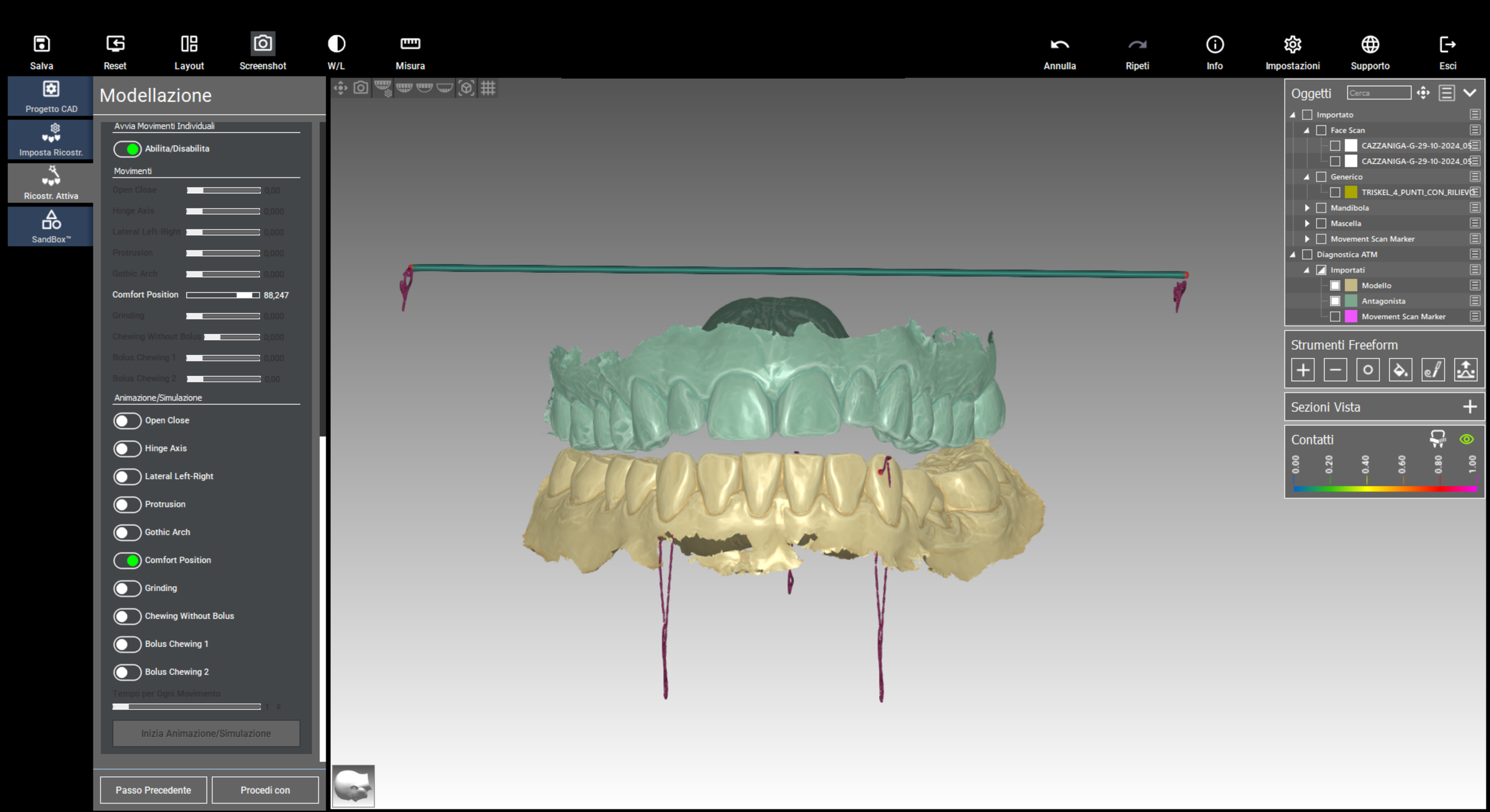
Salva
Reset
Layout
Screenshot
W/L
Misura
Annulla
Ripeti
Info
Impostazioni
Supporto
Esci
Progetto CAD
Imposta Ricostr.
Ricostr. Attiva
SandBox™
Modellazione
Avvia Movimenti Individuali
Abilita/Disabilita
Movimenti
Open Close
Hinge Axis
Lateral Left-Right
Protrusion
Gothic Arch
Comfort Position
88,247
Grinding
Chewing Without Bolus
Bolus Chewing 1
Bolus Chewing 2
Animazione/Simulazione
Open Close
Hinge Axis
Lateral Left-Right
Protrusion
Gothic Arch
Comfort Position
Grinding
Chewing Without Bolus
Bolus Chewing 1
Bolus Chewing 2
Tempo per Ogni Movimento
Inizia Animazione/Simulazione
Passo Precedente
Procedi con
Oggetti
Cerca
Importato
Face Scan
CAZZANIGA-G-29-10-2024_05
CAZZANIGA-G-29-10-2024_05
Generico
TRISKEL_4_PUNTI_CON_RILIEVO
Mandibola
Mascella
Movement Scan Marker
Diagnostica ATM
Importati
Modello
Antagonista
Movement Scan Marker
Strumenti Freeform
Sezioni Vista
Contatti
0.00
0.20
0.40
0.60
0.80
1.00

ITAKAD powered by RealGUIDE 5.4.0 CAD+ Membership scaduta
Salva
Reset
Layout
Screenshot
W/L
Misura
Annulla
Ripeti
Info
Impostazioni
Supporto
Esci
Progetto CAD
Imposta Ricostr.
Ricostr. Attiva
SandBox™
Modellazione
Aggiungi Piano
Duplica Ultimo
Elimina Ultimo
Elimina Tutti
Trasformazione Personalizzata
Marker Movimenti ATM
Mostra/Nascondi
Avvia Movimenti Individuali
Abilita/Disabilita
Movimenti
Open Close
Lateral Left-Right
Protrusion
Gothic Arch
Comfort Position
68,642
Chewing Without Bolus
Animazione/Simulazione
Open Close
Lateral Left-Right
Protrusion
Gothic Arch
Comfort Position
Chewing Without Bolus
Tempo per Ogni Movimento
10 s
Inizia Animazione/Simulazione
Passo Precedente
Procedi con
Oggetti
Cerca
Importato
Generico
TRISKEL_4_PUNTI_CON_RILIEVO
CAVALLI-F-20-11-2024_01-07-5
CAVALLI-F-20-11-2024_01-07-5
CAVALLI-F-20-11-2024_01-07-5
Movement Scan Marker
Mascella
Mandibola
Diagnostica ATM
Importati
Movement Scan Marker
Antagonista
Modello
Strumenti Freeform
Sezioni Vista
Contatti
0.00
0.20
0.40
0.60
0.80
1.00
02:01
-03:49

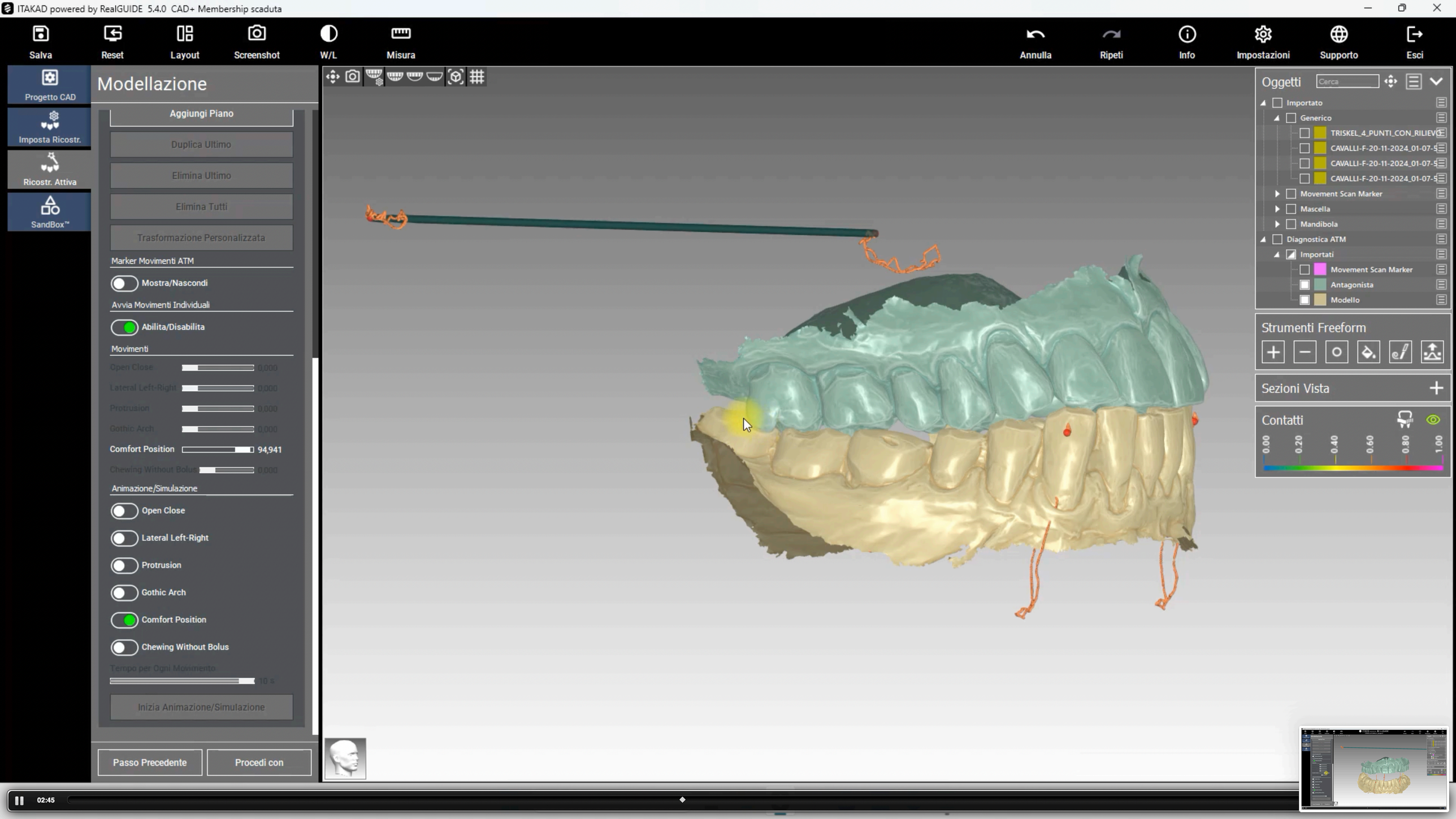
ITAKAD powered by RealGUIDE 5.4.0 CAD+ Membership scaduta
Salva
Reset
Layout
Screenshot
W/L
Misura
Annulla
Ripeti
Info
Impostazioni
Supporto
Esci
Progetto CAD
Imposta Ricostr.
Ricostr. Attiva
SandBox™
Modellazione
Aggiungi Piano
Duplica Ultimo
Elimina Ultimo
Elimina Tutti
Trasformazione Personalizzata
Marker Movimenti ATM
Mostra/Nascondi
Avvia Movimenti Individuali
Abilita/Disabilita
Movimenti
Open Close
Lateral Left-Right
Protrusion
Gothic Arch
Comfort Position
94,941
Chewing Without Bolus
Animazione/Simulazione
Open Close
Lateral Left-Right
Protrusion
Gothic Arch
Comfort Position
Chewing Without Bolus
Tempo per Ogni Movimento
Inizia Animazione/Simulazione
Passo Precedente
Procedi con
Oggetti
Cerca
Importato
Generico
TRISKEL_4_PUNTI_CON_RILIEVO
CAVALLI-F-20-11-2024_01-07-5
CAVALLI-F-20-11-2024_01-07-5
CAVALLI-F-20-11-2024_01-07-5
Movement Scan Marker
Mascella
Mandibola
Diagnostica ATM
Importati
Movement Scan Marker
Antagonista
Modello
Strumenti Freeform
Sezioni Vista
Contatti
0.00
0.20
0.40
0.60
0.80
1.00
02:45

Progetto CAD
Imposta Ricostr.
Ricostr. Attiva
SandBox™

Modellazione

Aggiungi Piano
Duplica Ultimo
Elimina Ultimo
Elimina Tutti
Trasformazione Personalizzata

Marker Movimenti ATM
Mostra/Nascondi

Avvia Movimenti Individuali
Abilita/Disabilita

Movimenti
Open Close 0,000
Lateral Left-Right 0,000
Protrusion 0,000
Gothic Arch 0,000
Comfort Position 100,000
Chewing Without Bolus 0,000

Animazione/Simulazione
Open Close
Lateral Left-Right
Protrusion
Gothic Arch
Comfort Position
Chewing Without Bolus
Tempo per Ogni Movimento 10 s
Inizia Animazione/Simulazione

Passo Precedente | Procedi con

Oggetti
Cerca
Importato
Generico
TRISKEL_4_PUNTI_CON_RILIEVO
CAVALLI-F-20-11-2024_01-07-5
CAVALLI-F-20-11-2024_01-07-5
CAVALLI-F-20-11-2024_01-07-5
Movement Scan Marker
Mascella
Mandibola
Diagnostica ATM
Importati
Movement Scan Marker
Antagonista
Modello

Strumenti Freeform

Sezioni Vista

Contatti
0.00 0.05 0.10 0.15 0.20 0.25

03:06

ITAKAD powered by RealGUIDE 5.4.0 CAD+ Membership scaduta
Salva
Reset
Layout
Screenshot
W/L
Misura
Annulla
Ripeti
Info
Impostazioni
Supporto
Esci
Progetto CAD
Imposta Ricostr.
Ricostr. Attiva
SandBox™
Modellazione
Aggiungi Piano
Duplica Ultimo
Elimina Ultimo
Elimina Tutti
Trasformazione Personalizzata
Marker Movimenti ATM
Mostra/Nascondi
Avvia Movimenti Individuali
Abilita/Disabilita
Movimenti
Open Close
Lateral Left-Right
Protrusion
Gothic Arch
Comfort Position
95,443
Chewing Without Bolus
Animazione/Simulazione
Open Close
Lateral Left-Right
Protrusion
Gothic Arch
Comfort Position
Chewing Without Bolus
Tempo per Ogni Movimento
Inizia Animazione/Simulazione
Passo Precedente
Procedi con
Oggetti
Cerca
Importato
Generico
TRISKEL_4_PUNTI_CON_RILIEVO
CAVALLI-F-20-11-2024_01-07-5
CAVALLI-F-20-11-2024_01-07-5
CAVALLI-F-20-11-2024_01-07-5
Movement Scan Marker
Mascella
Mandibola
Diagnostica ATM
Importati
Movement Scan Marker
Antagonista
Modello
Strumenti Freeform
Sezioni Vista
Contatti
0.00
0.05
0.10
0.15
0.20
0.25
05:16



Primi tracciati

Asimmetrici

Seconda

registrazione



Tracciati più simmetrici nella seconda registrazione ,

I primi avevano una prevalenza dx

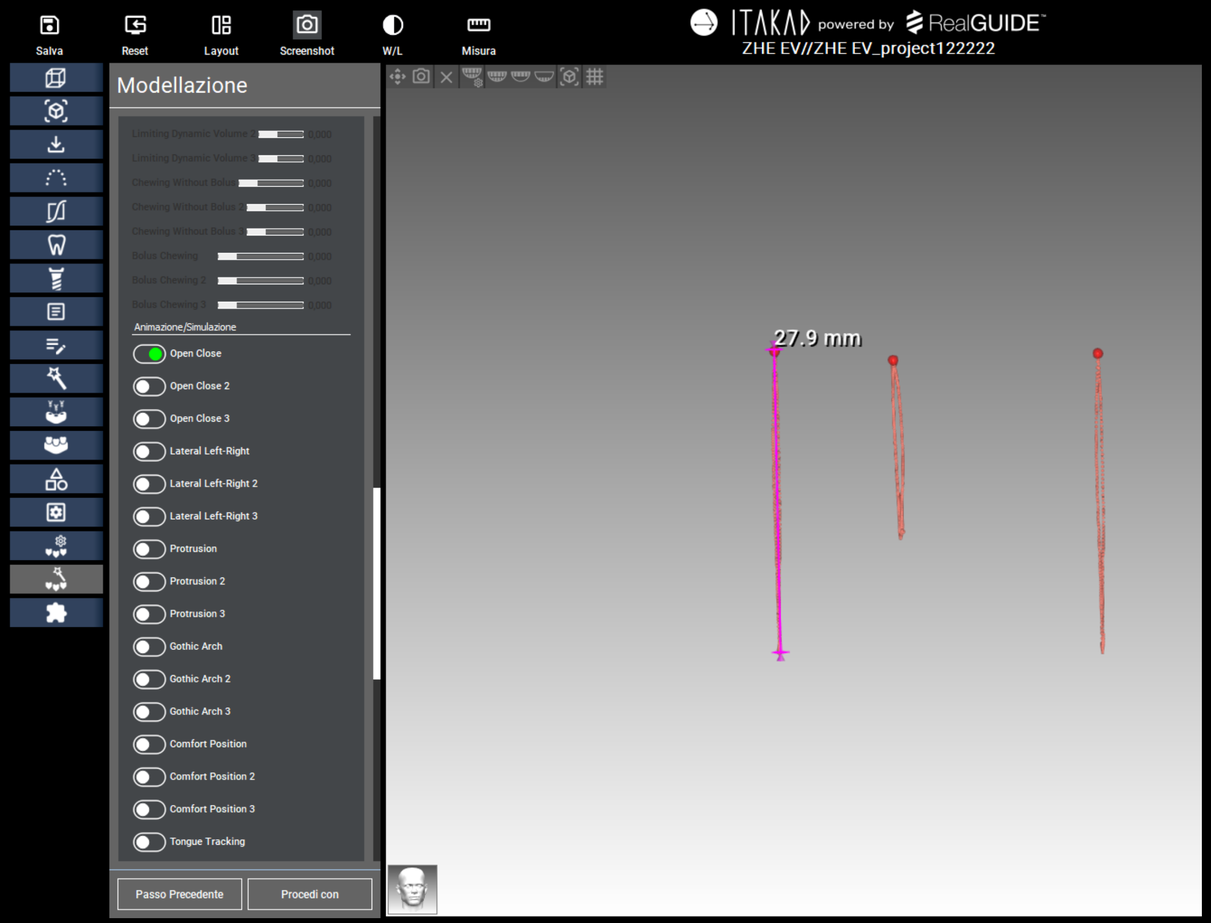

T 0

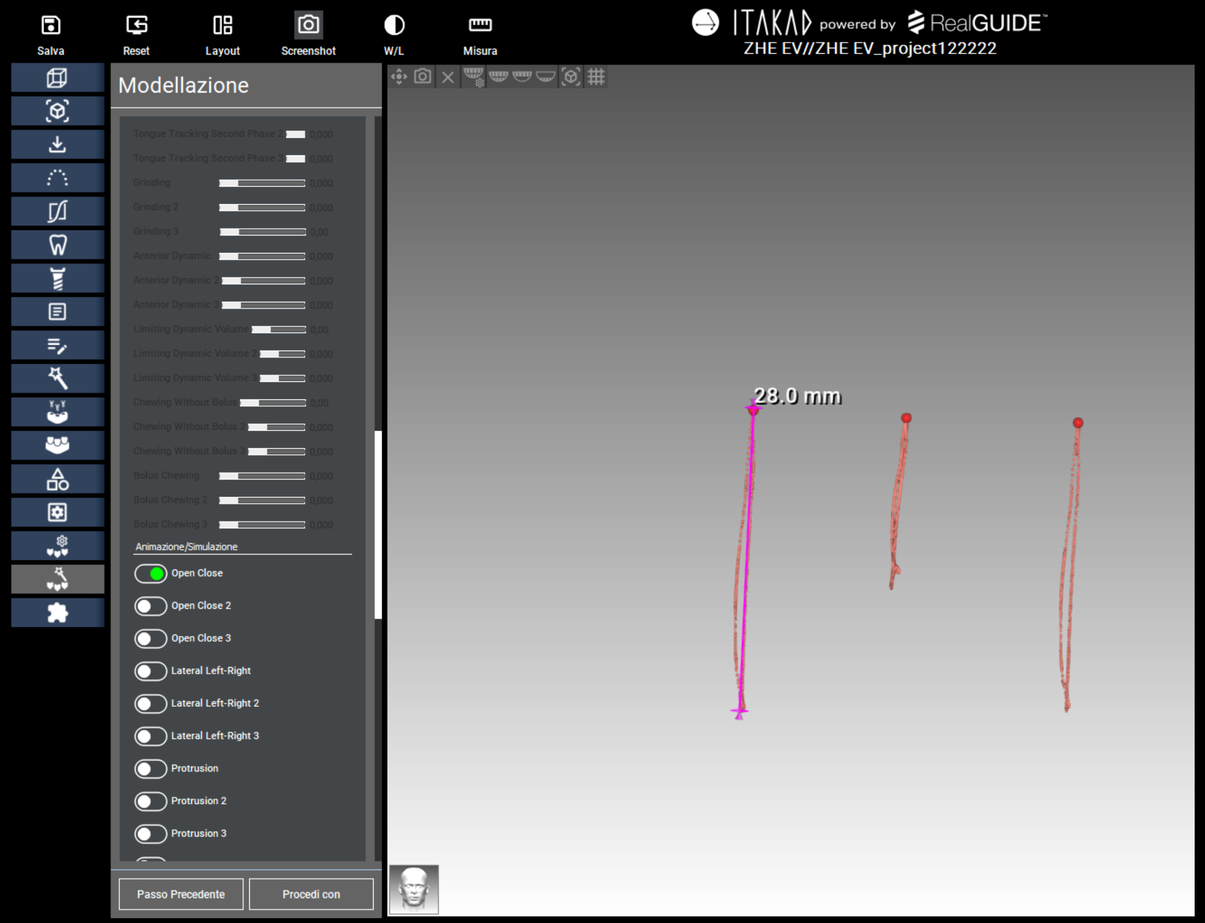

T 1

Confronto apertura chiusura

Apertura chiusura simili , solo una leggera escursione nella seconda

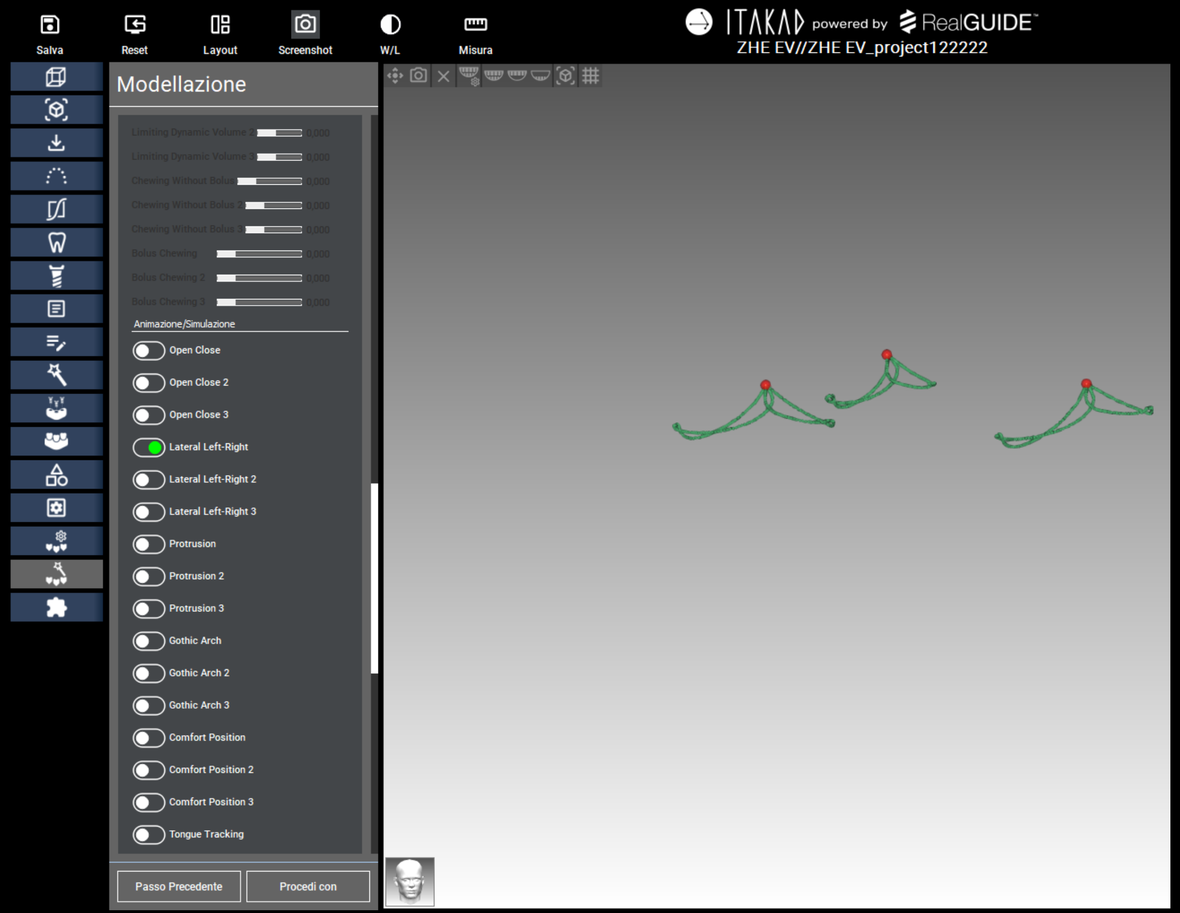

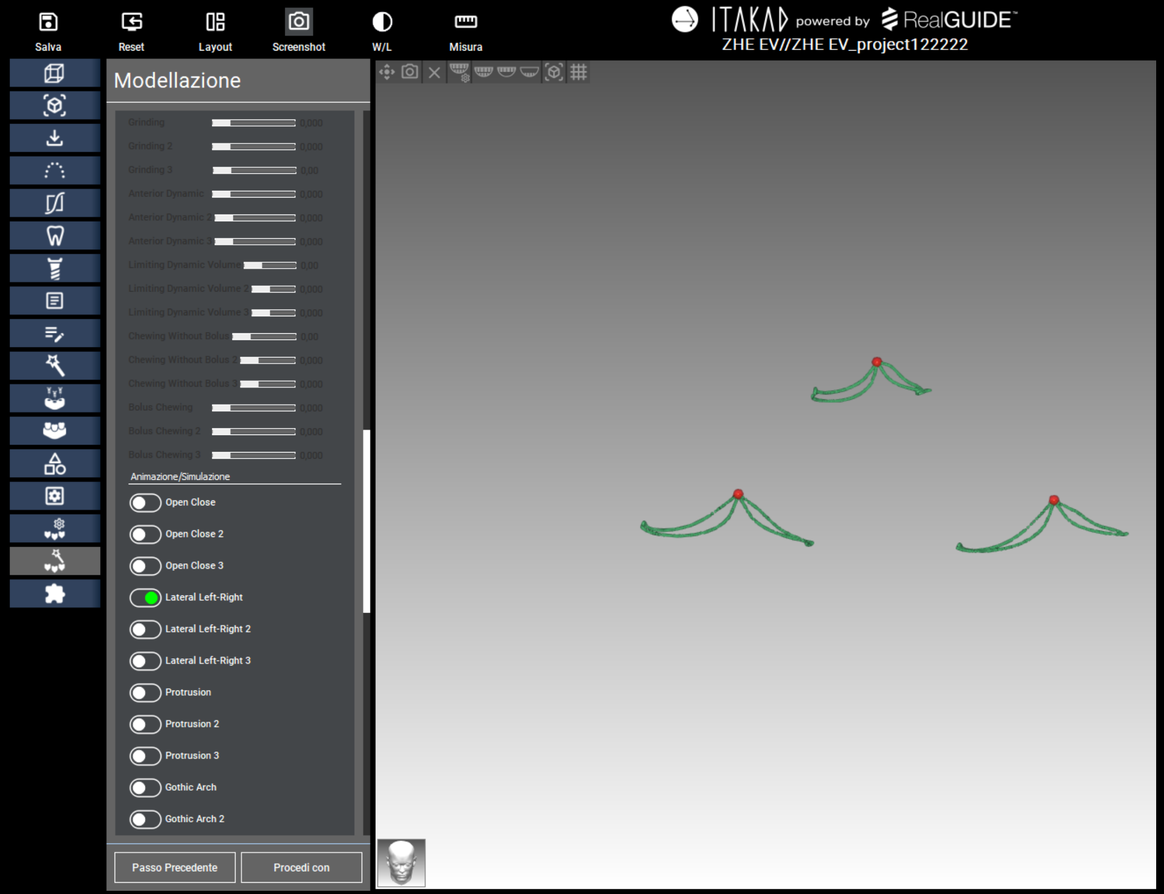

T 0

T 1

CONFRONTO LATERALITA’

Tracciati laterali più lineari nella seconda

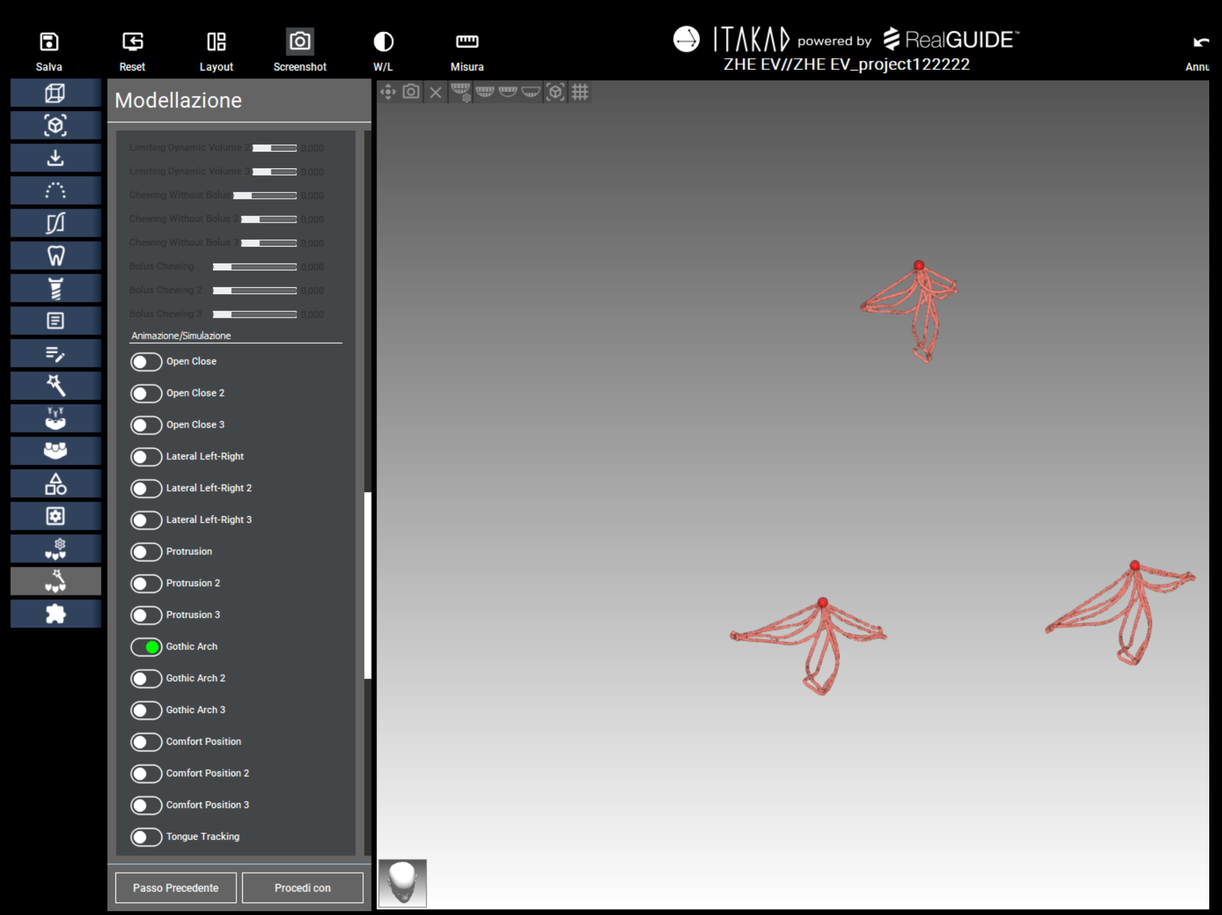

T 0

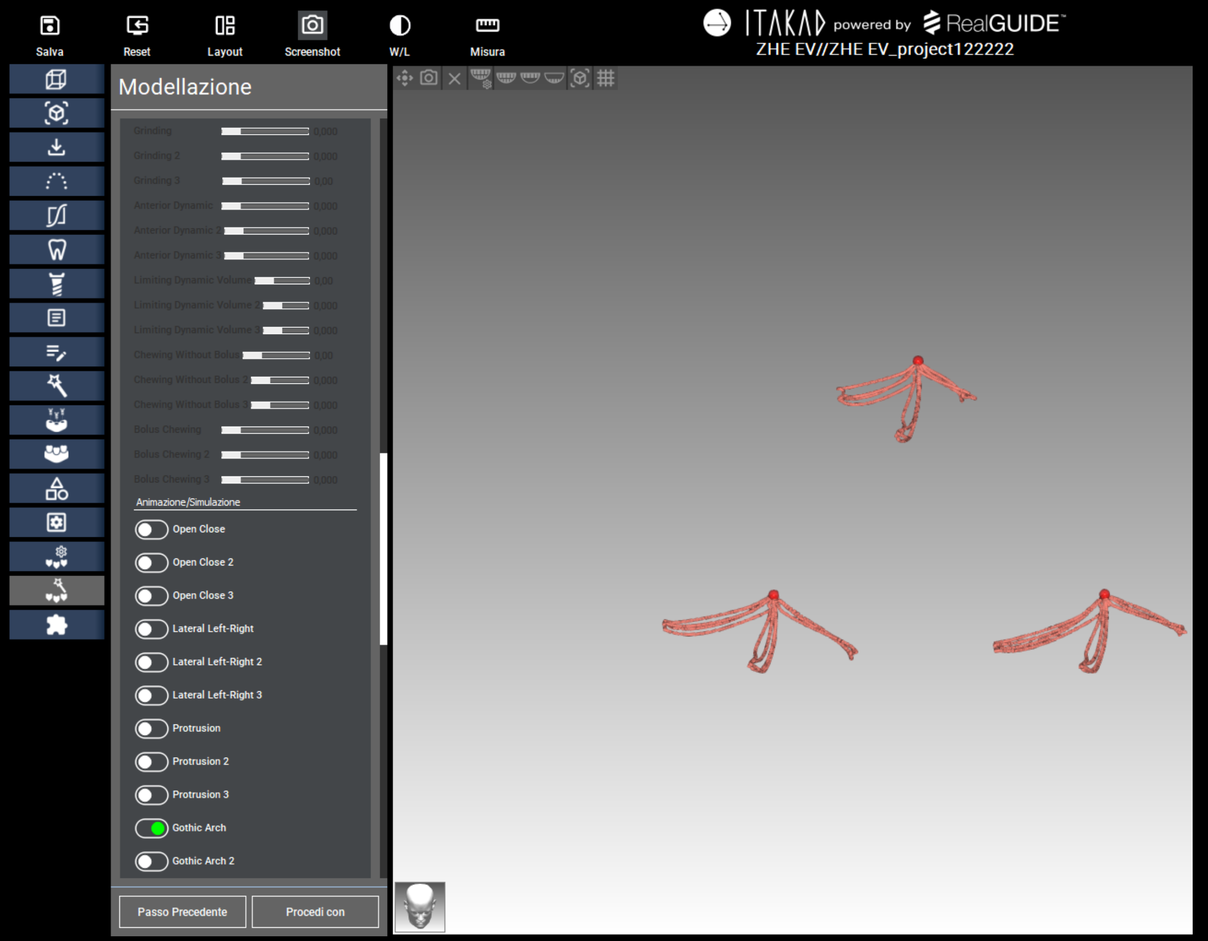

T 1

CONFRONTO ARCO GOTICO

Arco gotico più funzionale nella seconda , tracciato pulito pur rispettando una leggera propria asimmetria

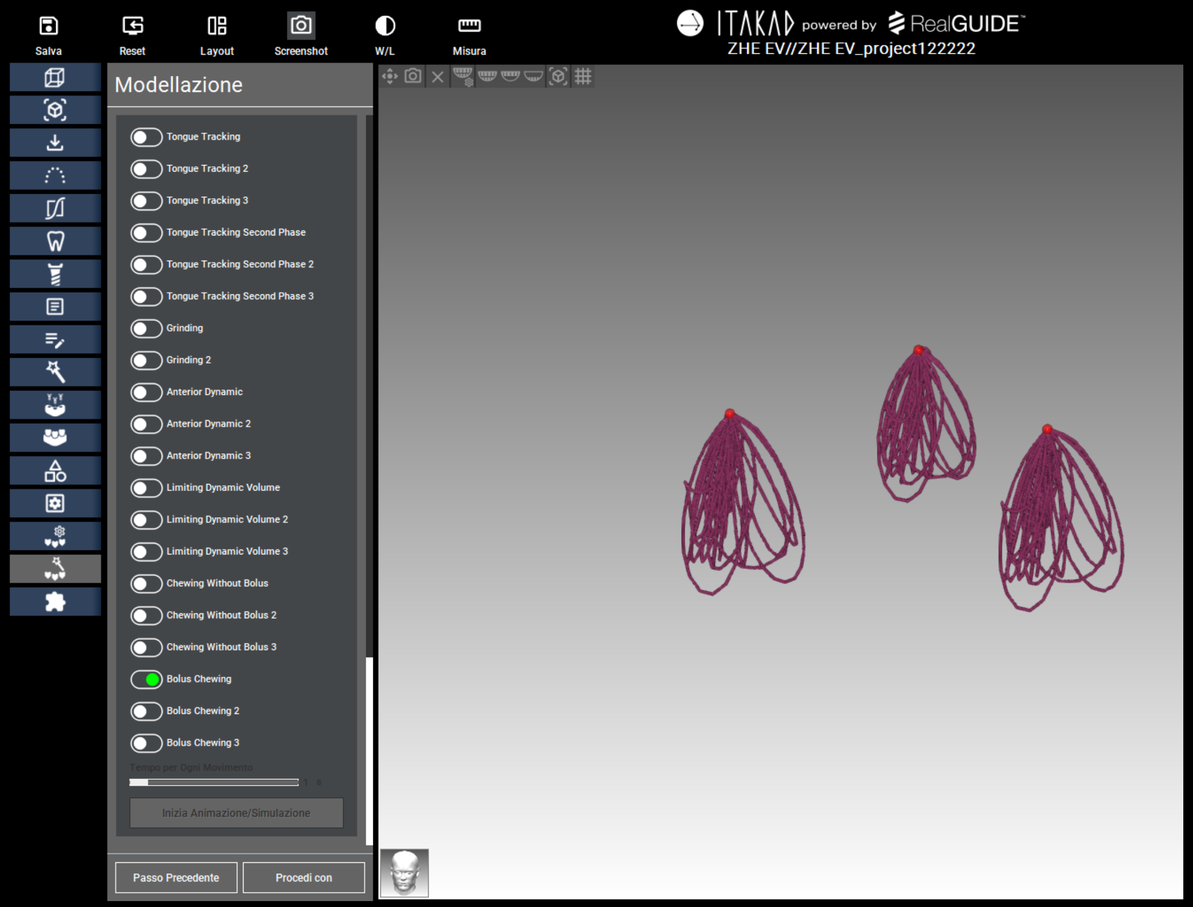

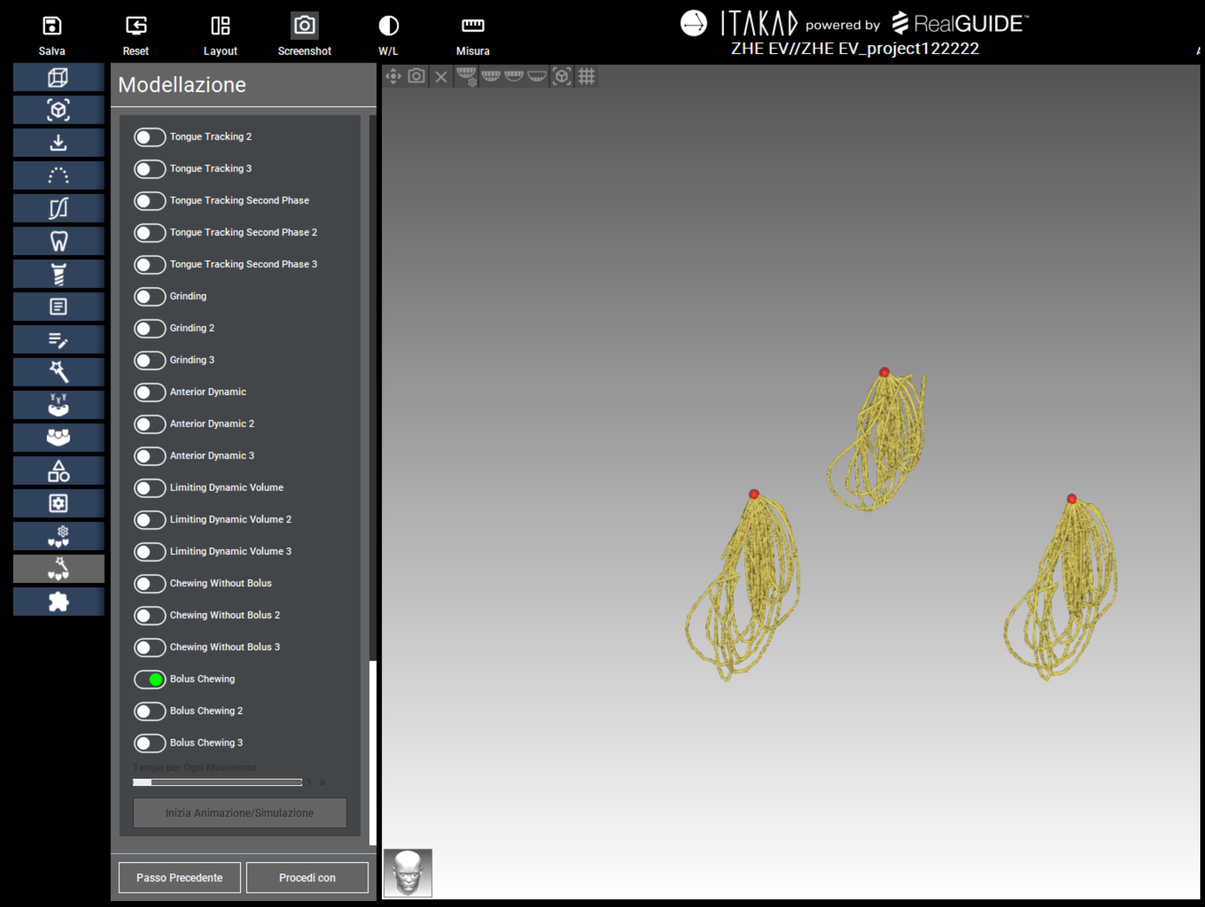

T0

CONFRONTO BOLUS CHEWING

T 1

Tracciato di chewing che conferma la riprogrammazione funzionale ,

nella prima una ovvia prevalenza dx ,nella seconda funzione dinamica più uniforme

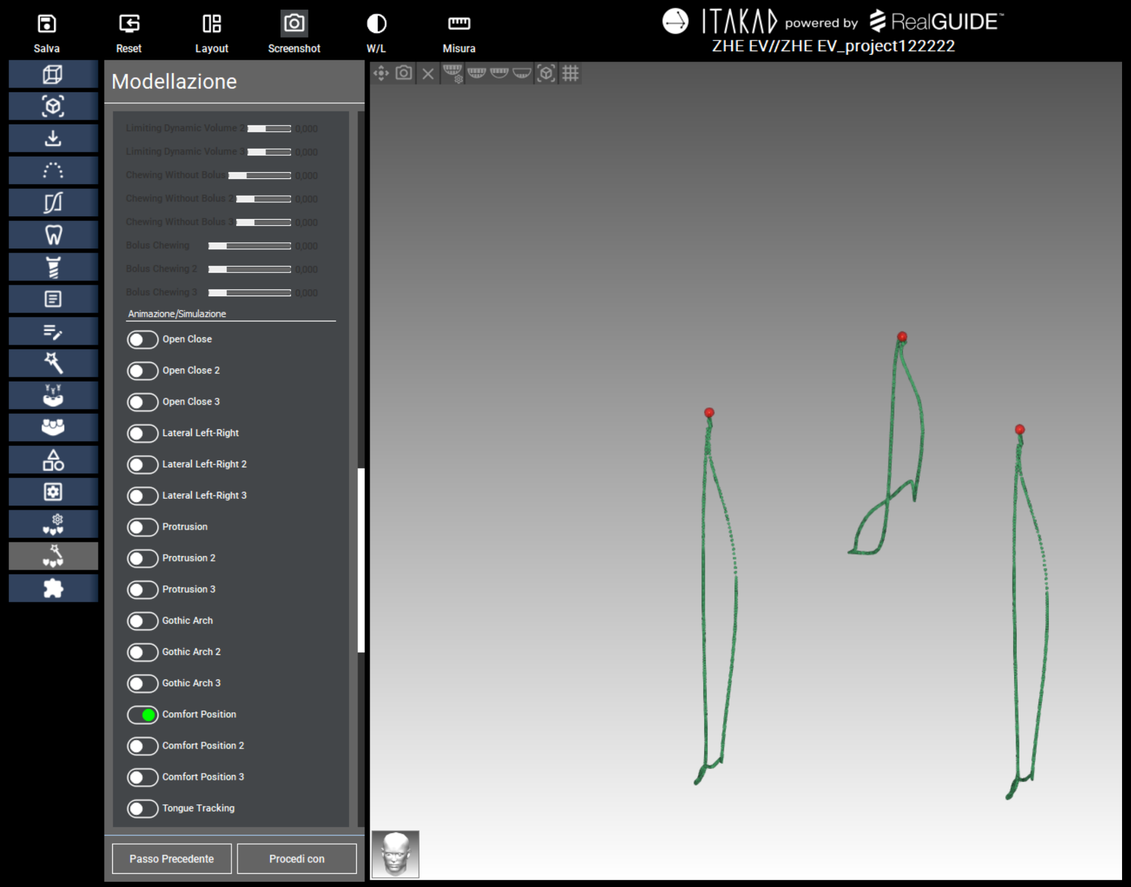

T 0

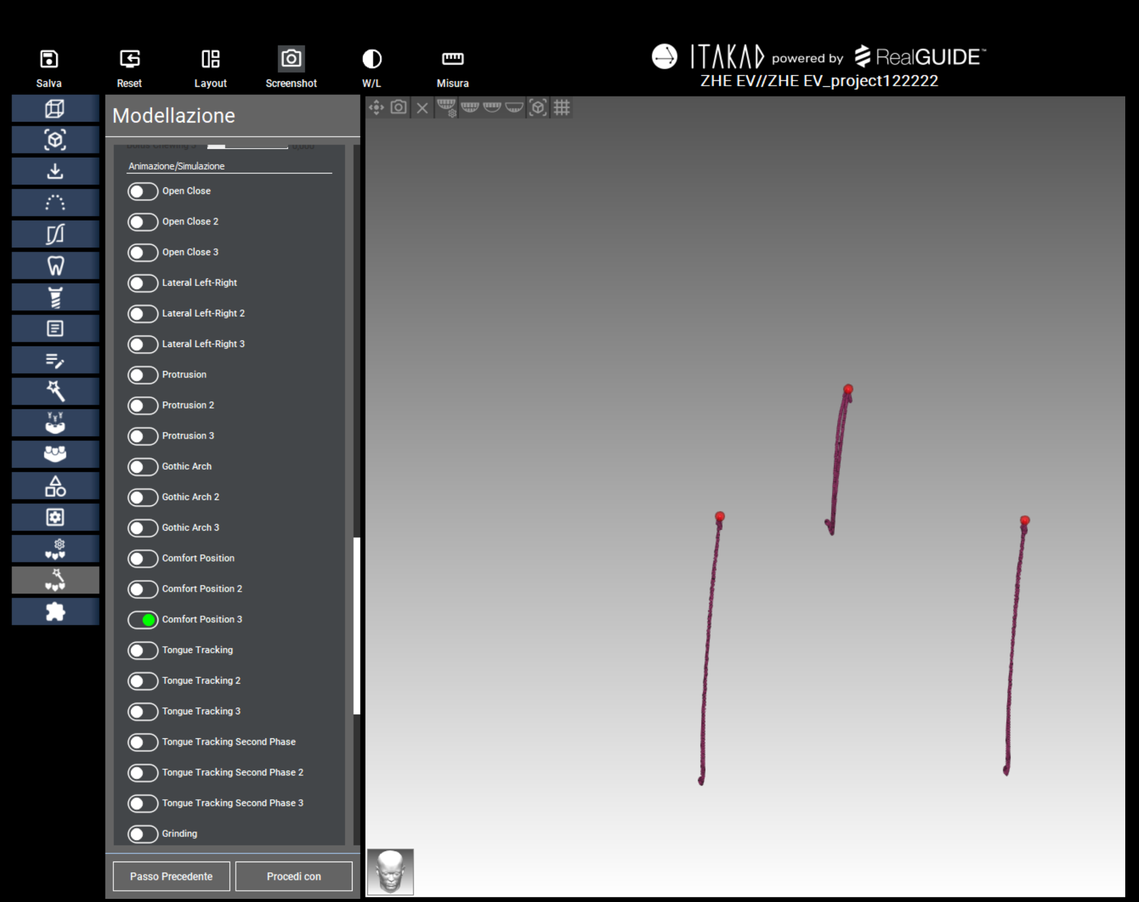

T 1

COMFORT POSITION CONFRONTO

















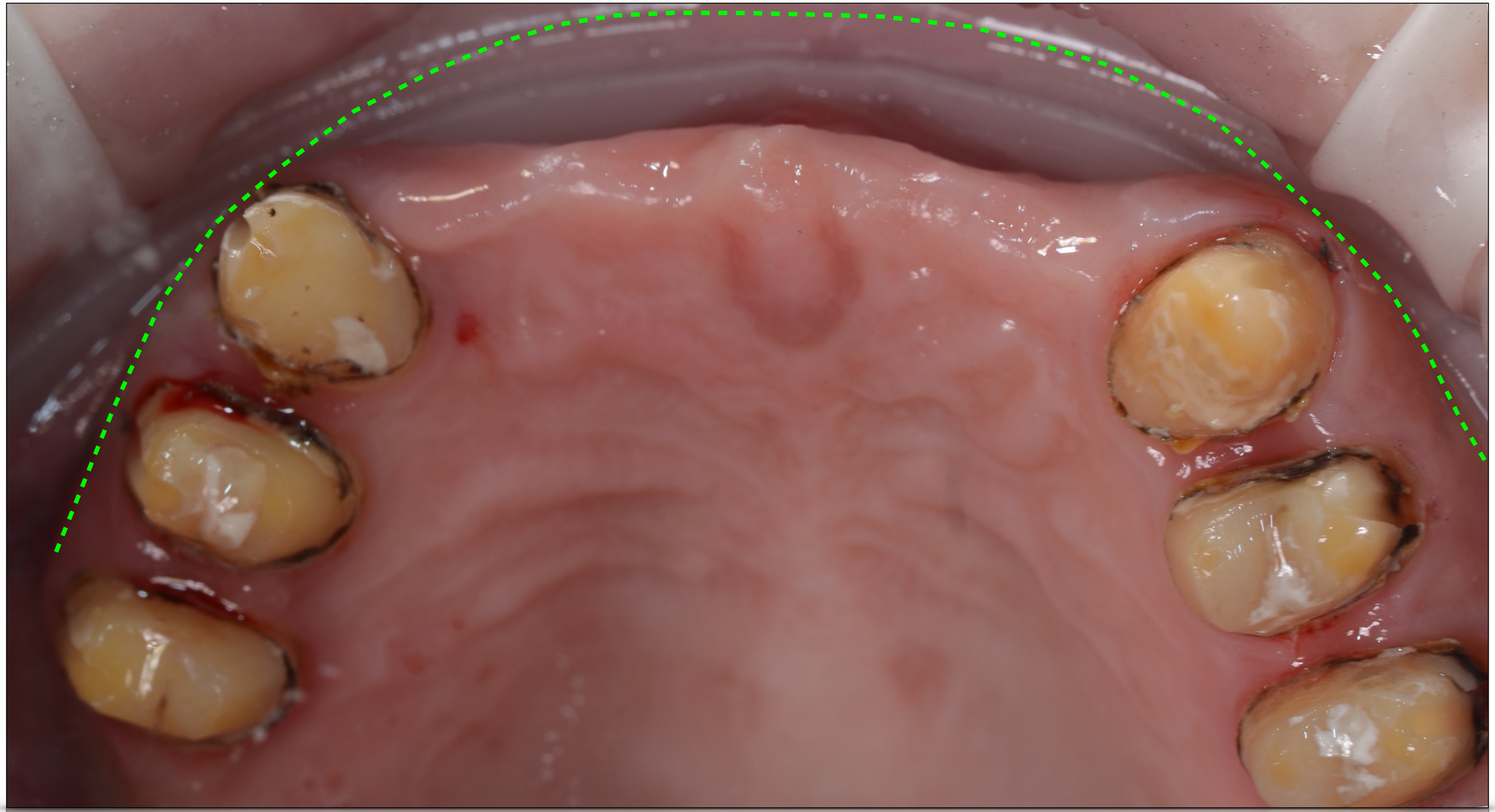

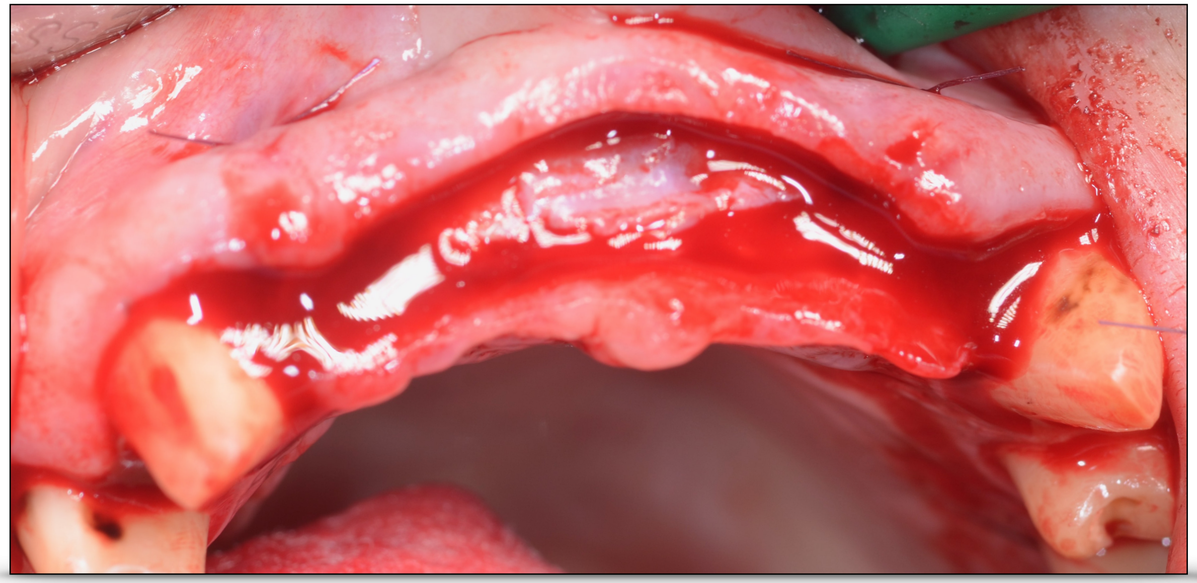



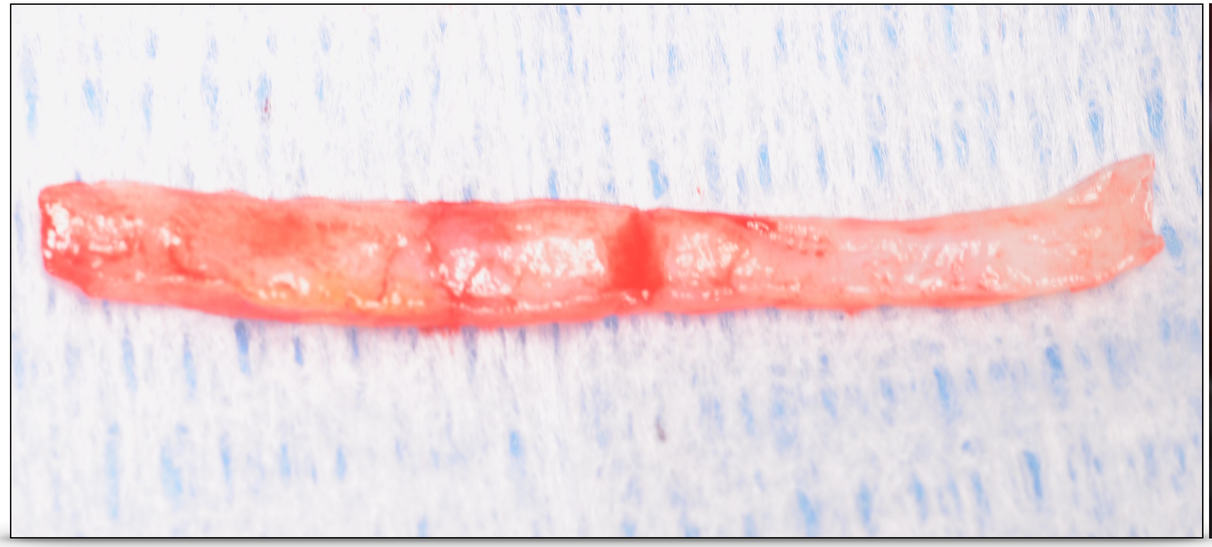







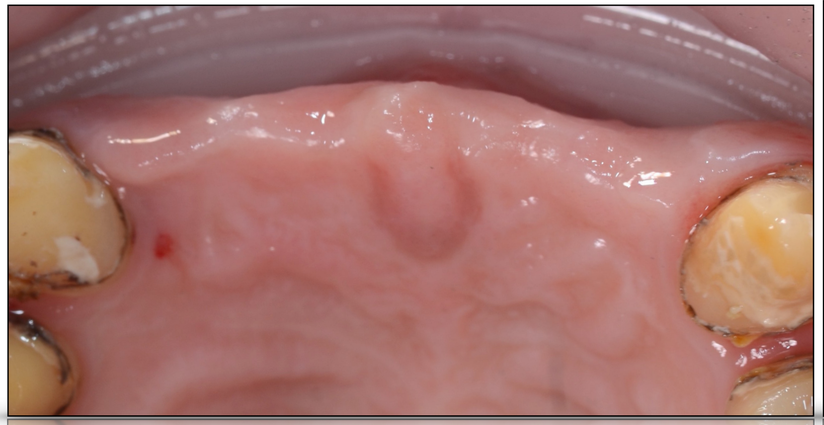

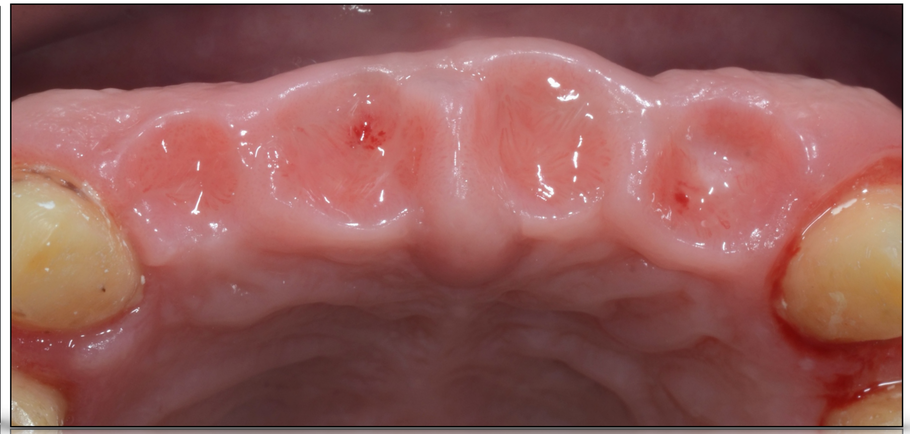

Gruppi

- Antagonista
- Modelli master 100%
- Abutment di scansione
- Scansione facciale
  - metascan_20240801-1055.ob...
  - metascan_20240801-1057.ob...
  - metascan_20240801-1058.ob...
- Oggetto per visualizzazione
  - modellazione sup.stl (18-...-27...
  - Soares da Silva Sandra.stl (18...
- Registrazione occlusale
- mandibola.stl (37-...-48)
- modellazione sup.stl (18-...-26)

Denti

Nascosto Nascondi automaticamente



Salva

Wizard

Strumenti

Mostra distanza

TruSmile

Vista in sezione

Aggiungi vista personalizzata

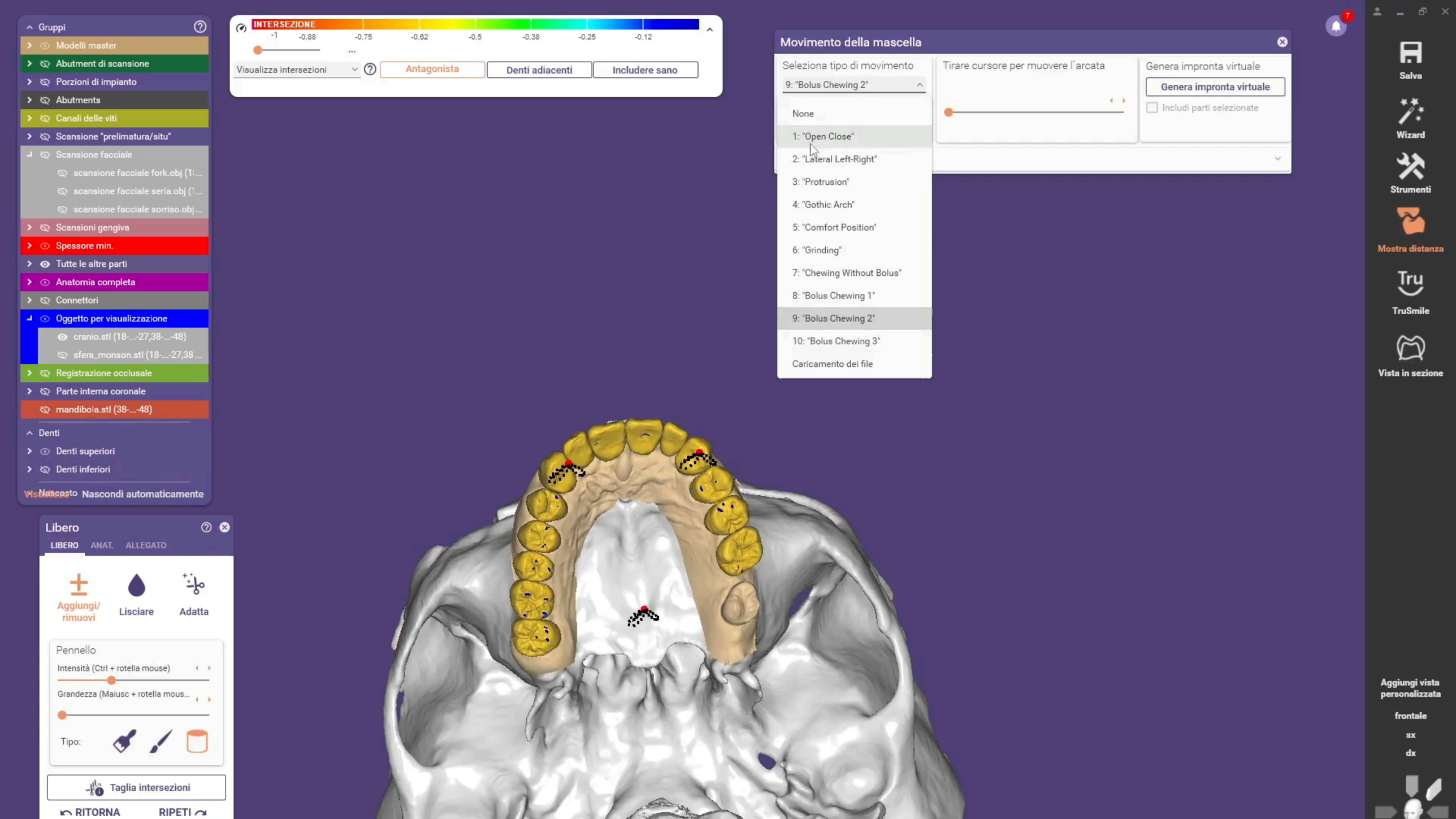
Gruppi
Modelli master
Abutment di scansione
Porzioni di impianto
Abutments
Canali delle viti
Scansione "prelimatura/situ"
Scansione facciale
scansione facciale fork.obj (1...
scansione facciale seria.obj (1...
scansione facciale sorriso.obj ...
Scansioni gengiva
Spessore min.
Tutte le altre parti
Anatomia completa
Connettori
Oggetto per visualizzazione
cranio.stl (18-...-27,38-...-48)
sfera_monson.stl (18-...-27,38 ...
Registrazione occlusale
Parte interna coronale
mandibola.stl (38-...-48)
Denti
Denti superiori
Denti inferiori
Nascosto
Nascondi automaticamente
INTERSEZIONE
-1
-0,88
-0,75
-0,62
-0,5
-0,38
-0,25
-0,12
Visualizza intersezioni
Antagonista
Denti adiacenti
Includere sano
Movimento della mascella
Seleziona tipo di movimento
9: "Bolus Chewing 2"
None
1: "Open Close"
2: "Lateral Left-Right"
3: "Protrusion"
4: "Gothic Arch"
5: "Comfort Position"
6: "Grinding"
7: "Chewing Without Bolus"
8: "Bolus Chewing 1"
9: "Bolus Chewing 2"
10: "Bolus Chewing 3"
Caricamento dei file
Tirare cursore per muovere l'arcata
Genera impronta virtuale
Genera impronta virtuale
Includi parti selezionate
Salva
Wizard
Strumenti
Mostra distanza
TruSmile
Vista in sezione
Aggiungi vista personalizzata
frontale
sx
dx
Libero
LIBERO
ANAT.
ALLEGATO
Aggiungi/ rimuovi
Lisciare
Adatta
Pennello
Intensità (Ctrl + rotella mouse)
Grandezza (Maiusc + rotella mous...
Tipo:
Taglia intersezioni
RITORNA
RIPETI



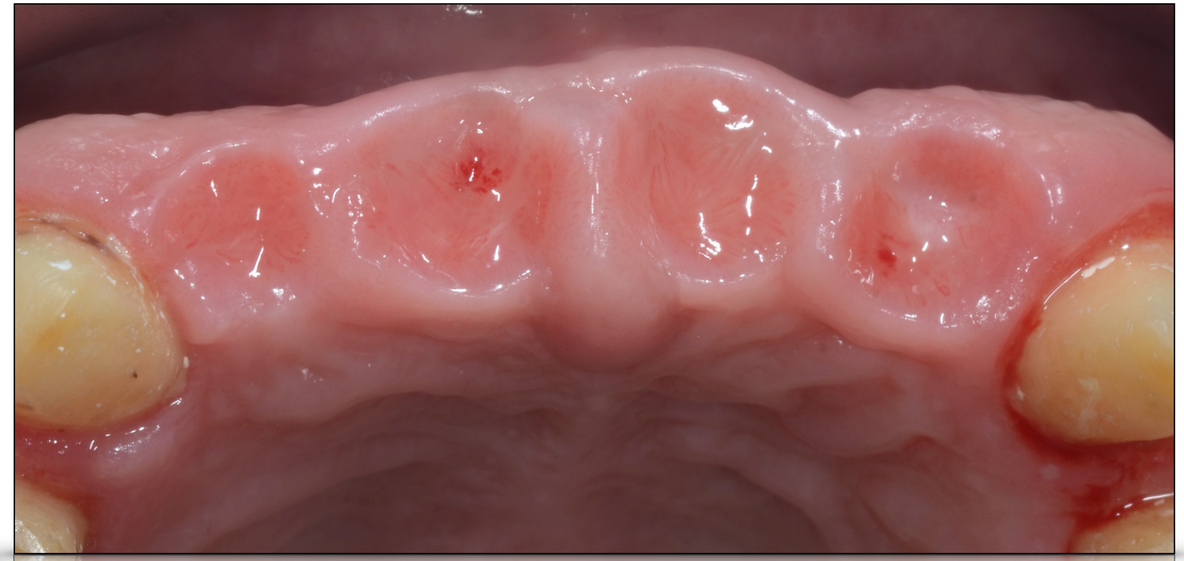



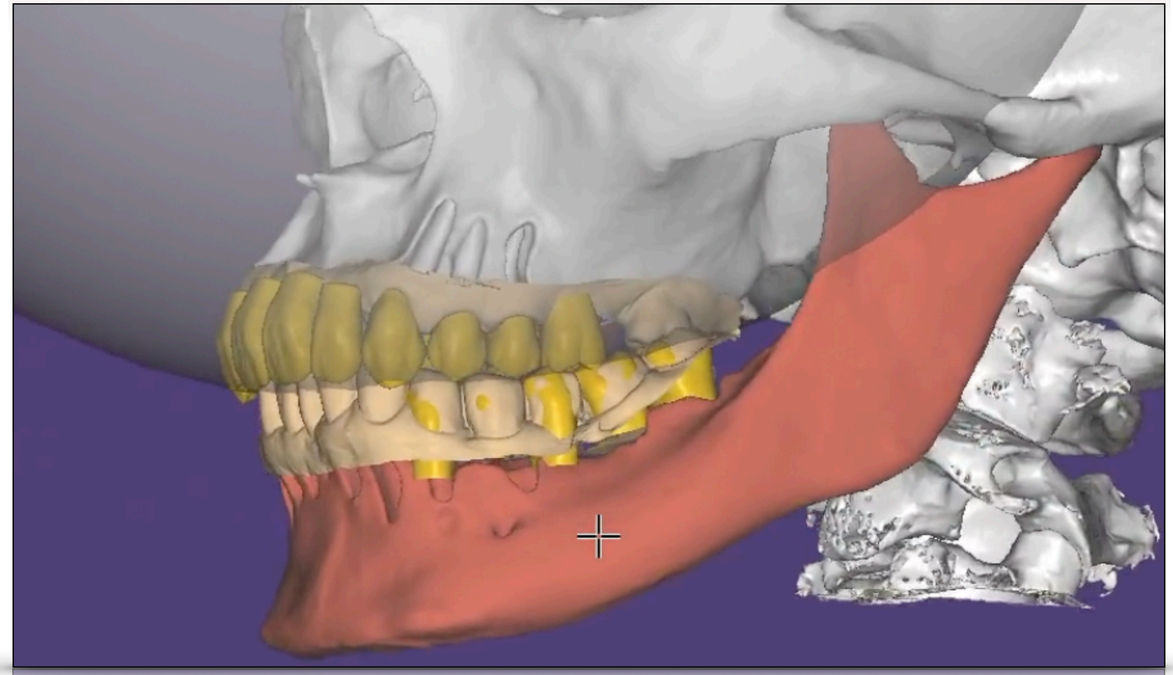











































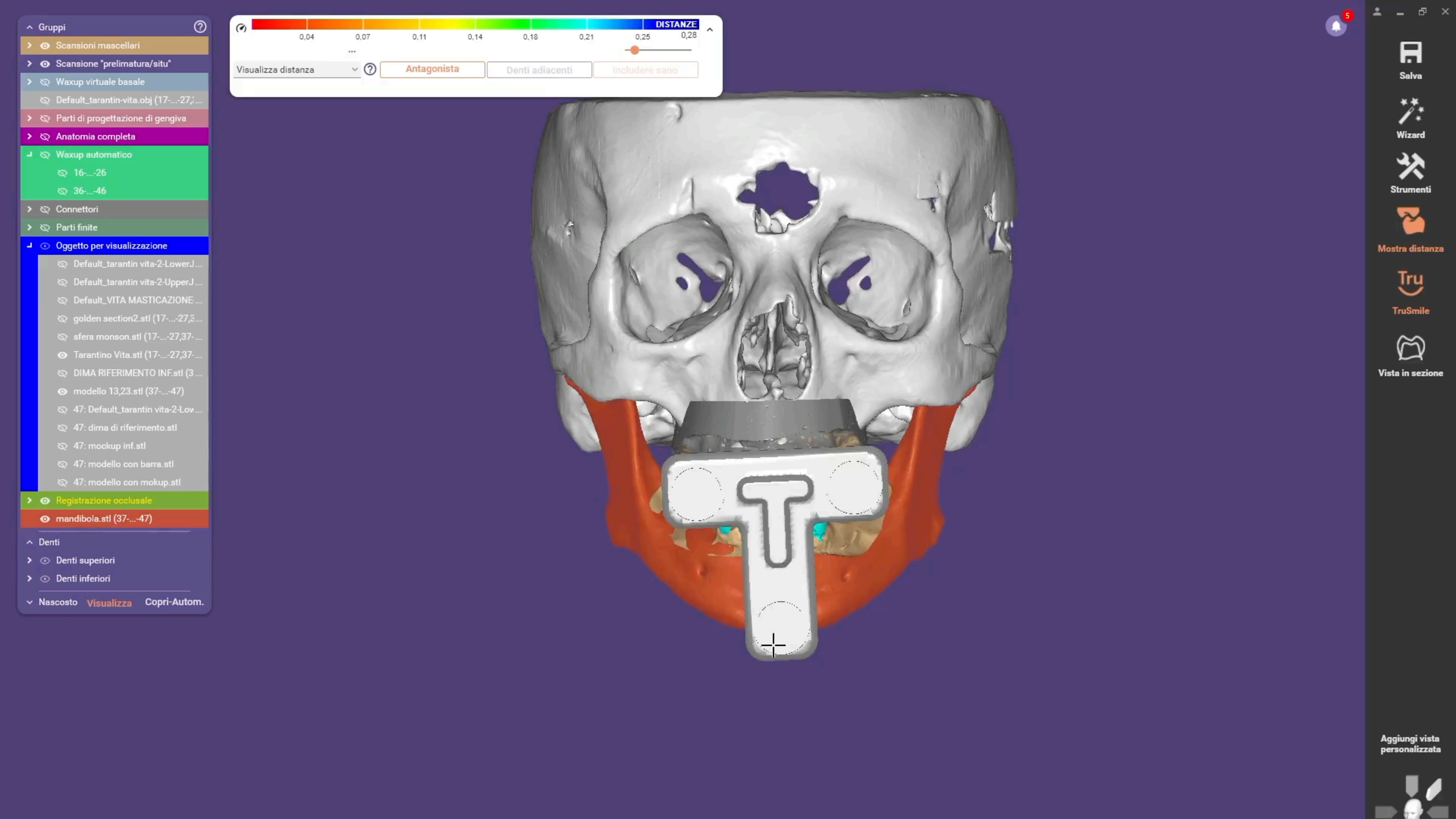
Gruppi
Scansioni mascellari
Scansione "prelimatura/situ"
Waxup virtuale basale
Default_tarantin-vita.obj (17-...-27,...
Parti di progettazione di gengiva
Anatomia completa
Waxup automatico
16-...-26
36-...-46
Connettori
Parti finite
Oggetto per visualizzazione
Default_tarantin vita-2-LowerJ...
Default_tarantin vita-2-UpperJ...
Default_VITA MASTICAZIONE...
golden section2.stl (17-...-27,3...
sfera monson.stl (17-...-27,37-...
Tarantino Vita.stl (17-...-27,37-...
DIMA RIFERIMENTO INF.stl (3...
modello 13,23.stl (37-...-47)
47: Default_tarantin vita-2-Lov...
47: dima di riferimento.stl
47: mockup inf.stl
47: modello con barra.stl
47: modello con mokup.stl
Registrazione occlusale
mandibola.stl (37-...-47)
Denti
Denti superiori
Denti inferiori
Nascosto
Visualizza
Copri-Autom.
DISTANZE
0,04
0,07
0,11
0,14
0,18
0,21
0,25
0,28
Visualizza distanza
Antagonista
Denti adiacenti
Includere sano
Salva
Wizard
Strumenti
Mostra distanza
TruSmile
Vista in sezione
Aggiungi vista personalizzata

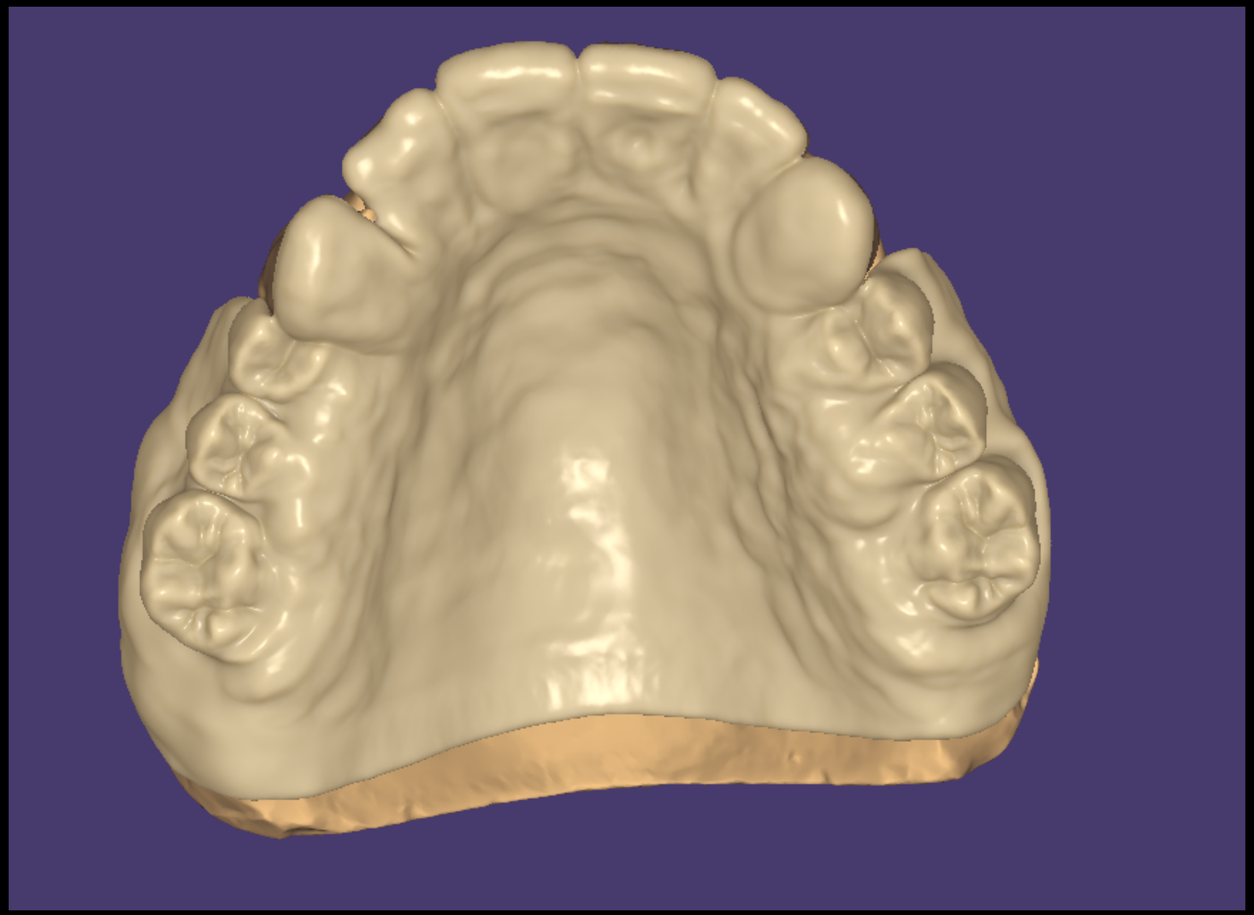

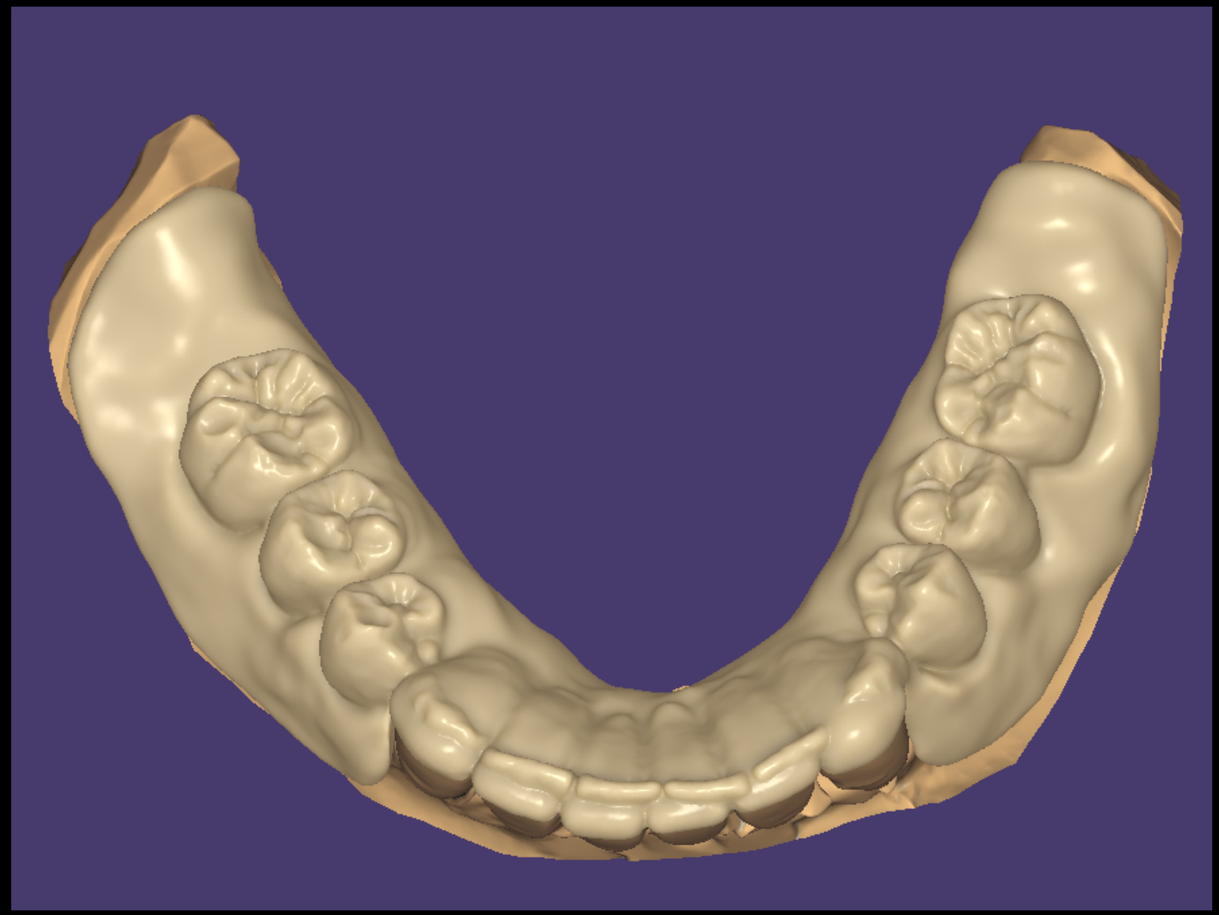










R

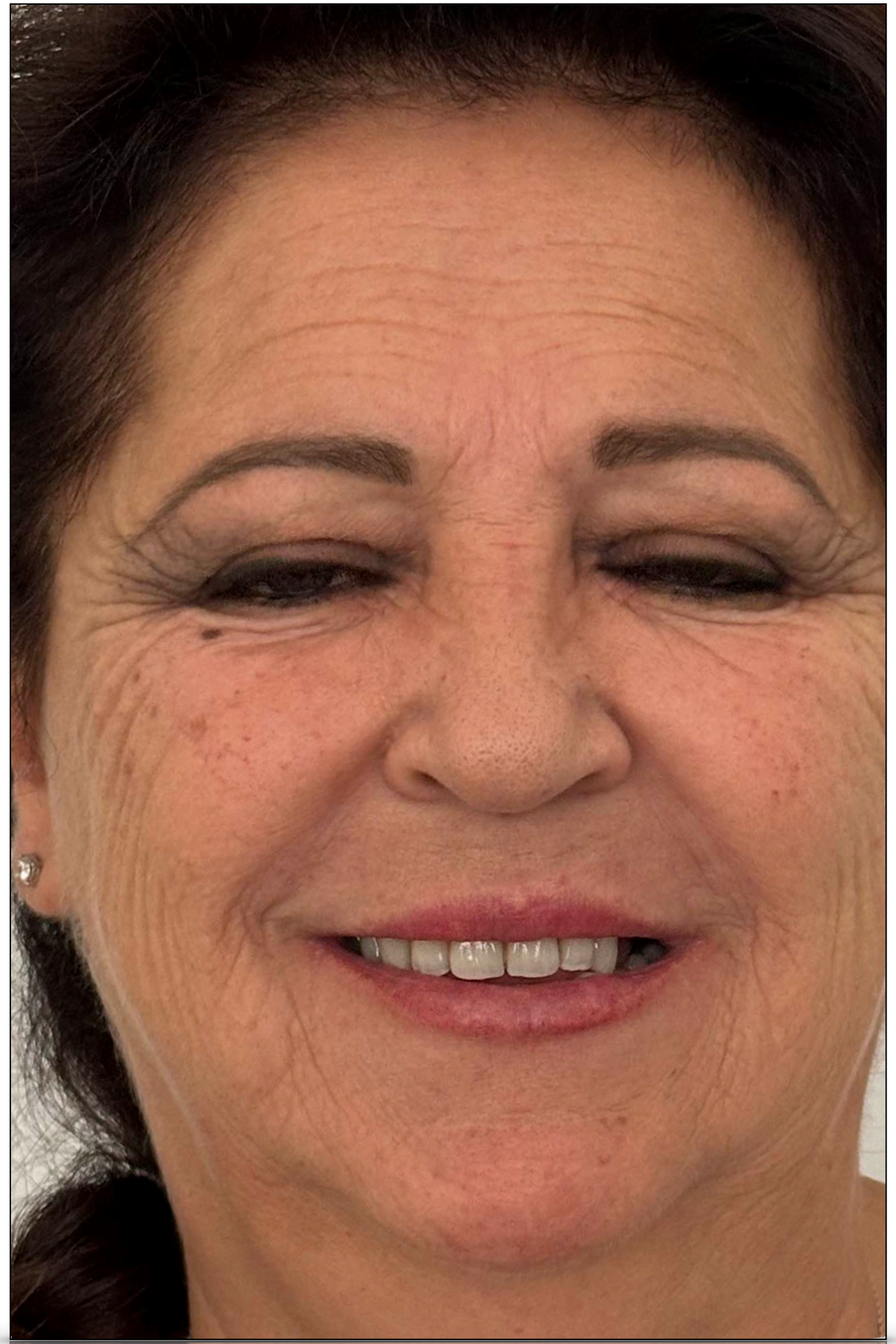








R
L



Received: 10 December 2017 | Revised: 12 March 2018 | Accepted: 13 March 2018

DOI: 10.1002/JPER.17-0721

2017 WORLD WORKSHOP

JOURNAL OF Periodontology

Periodontitis: Consensus report of workgroup 2 of the 2017 World Workshop on the Classification of Periodontal and Peri-Implant Diseases and Conditions

Panos N. Papapanou[1] | Mariano Sanz[2] | Nurcan Buduneli[3] | Thomas Dietrich[4] | Magda Feres[5] | Daniel H. Fine[6] | Thomas F. Flemmig[7] | Raul Garcia[8] | William V. Giannobile[9] | Filippo Graziani[10] | Henry Greenwell[11] | David Herrera[2] | Richard T. Kao[12] | Moritz Kebschull[1,13] | Denis F. Kinane[14] | Keith L. Kirkwood[15] | Thomas Kocher[16] | Kenneth S. Kornman[9] | Purnima S. Kumar[17] | Bruno G. Loos[18] | Eli Machtei[19] | Huanxin Meng[20] | Andrea Mombelli[21] | Ian Needleman[22] | Steven Offenbacher[23] | Gregory J. Seymour[24] | Ricardo Teles[14] | Maurizio S. Tonetti[7]

[1]Columbia University, New York, NY, USA
[2]Universidad Complutense Madrid, Madrid, Spain
[3]Ege University, Izmir, Turkey
[4]University of Birmingham, Birmingham, United Kingdom
[5]Universidade Guarulhos, Guarulhos, Brazil
[6]Rutgers University, Newark, NJ, USA
[7]University of Hong Kong, Hong Kong, SAR China
[8]Boston University, Boston, MA, USA
[9]University of Michigan, Ann Arbor, MI, USA
[10]University of Pisa, Pisa, Italy
[11]University of Louisville, Louisville, KY, USA
[12]Private practice, Cupertino, CA, USA
[13]Bonn University, Bonn, Germany
[14]University of Pennsylvania, Philadelphia, PA, USA
[15]University at Buffalo, Buffalo, NY, USA
[16]Greifswald University, Greifswald, Germany
[17]The Ohio State University, Columbus, OH, USA
[18]Academic Center for Dentistry (ACTA), University of Amsterdam and Vrije Universiteit Amsterdam, Amsterdam, The Netherlands
[19]Rambam Health Care Campus & Israel Institute of Technology, Haifa, Israel
[20]Peking University, Beijing, China
[21]University of Geneva, Geneva, Switzerland
[22]University College London, London, United Kingdom
[23]University of North Carolina, Chapel Hill, NC, USA
[24]University of Queensland, Brisbane, Australia

© 2018 American Academy of Periodontology and European Federation of Periodontology

Correspondence
Dr. Panos N. Papapanou, Division of Periodontics, Section of Oral, Diagnostic and Rehabilitation Sciences, Columbia University College of Dental Medicine, 630 West 168th Street, PH-7E-110, New York, NY 10032, USA.
Email: pp192@cumc.columbia.edu

Sources of Funding: The workshop was planned and conducted jointly by the American Academy of Periodontology and the European Federation of Periodontology with financial support from the American Academy of Periodontology Foundation, Colgate, Johnson & Johnson Consumer Inc., Geistlich Biomaterials, SUNSTAR, and Procter & Gamble Professional Oral Health.

The proceedings of the workshop were jointly and simultaneously published in the *Journal of Periodontology* and *Journal of Clinical Periodontology*.

Abstract

A new periodontitis classification scheme has been adopted, in which forms of the disease previously recognized as "chronic" or "aggressive" are now grouped under a single category ("periodontitis") and are further characterized based on a multidimensional *staging* and *grading* system. S*taging* is largely dependent upon the severity of disease at presentation as well as on the complexity of disease management, while *grading* provides supplemental information about biological features of the disease including a history-based analysis of the rate of periodontitis progression; assessment of the risk for further progression; analysis of possible poor outcomes of treatment; and assessment of the risk that the disease or its treatment may negatively affect the general health of the patient.

Necrotizing periodontal diseases, whose characteristic clinical phenotype includes typical features (papilla necrosis, bleeding, and pain) and are associated with host immune response impairments, remain a distinct periodontitis category.

Endodontic-periodontal lesions, defined by a pathological communication between the pulpal and periodontal tissues at a given tooth, occur in either an acute or a chronic form, and are classified according to signs and symptoms that have direct impact on their prognosis and treatment.

Periodontal abscesses are defined as acute lesions characterized by localized accumulation of pus within the gingival wall of the periodontal pocket/sulcus, rapid tissue destruction and are associated with risk for systemic dissemination.

KEYWORDS

acute periodontal conditions, endo-periodontal lesion, necrotizing gingivitis, necrotizing periodontitis, periodontal abscess, periodontal disease, periodontitis

Periodontitis is a chronic multifactorial inflammatory disease associated with dysbiotic plaque biofilms and characterized by progressive destruction of the tooth-supporting apparatus. Its primary features include the loss of periodontal tissue support, manifested through clinical attachment loss (CAL) and radiographically assessed alveolar bone loss, presence of periodontal pocketing and gingival bleeding. Periodontitis is a major public health problem due to its high prevalence, as well as because it may lead to tooth loss and disability, negatively affect chewing function and aesthetics, be a source of social inequality, and impair quality of life. Periodontitis accounts for a substantial proportion of edentulism and masticatory dysfunction, results in significant dental care costs and has a plausible negative impact on general health.

According to the latest internationally accepted classification scheme (Armitage[1] 1999), *periodontitis* is further subdivided as follows:

- *Chronic periodontitis*, representing the forms of destructive periodontal disease that are generally characterized by slow progression
- *Aggressive periodontitis,* a diverse group of highly destructive forms of periodontitis affecting primarily young individuals, including conditions formerly classified as "early-onset periodontitis" and "rapidly progressing periodontitis"
- *Periodontitis as a manifestation of systemic disease,* a heterogeneous group of systemic pathological conditions that include periodontitis as a manifestation
- *Necrotizing periodontal diseases,* a group of conditions that share a characteristic phenotype where necrosis of the gingival or periodontal tissues is a prominent feature
- *Periodontal abscesses,* a clinical entity with distinct diagnostic features and treatment requirements

Although the above classification has provided a workable framework that has been used extensively in both clinical practice and scientific investigation in periodontology during the past 17 years, the system suffers from several important shortcomings, including substantial overlap and lack of clear pathobiology-based distinction between the stipulated

JOURNAL OF Periodontology

TABLE 1A Classification of periodontitis based on stages defined by severity (according to the level of interdental clinical attachment loss, radiographic bone loss and tooth loss), complexity and extent and distribution

Periodontitis stage		Stage I	Stage II	Stage III	Stage IV
Severity	**Interdental CAL at site of greatest loss**	1 to 2 mm	3 to 4 mm	≥5 mm	≥5 mm
	Radiographic bone loss	Coronal third (<15%)	Coronal third (15% to 33%)	Extending to mid-third of root and beyond	Extending to mid-third of root and beyond
	Tooth loss	No tooth loss due to periodontitis		Tooth loss due to periodontitis of ≤4 teeth	Tooth loss due to periodontitis of ≥5 teeth
Complexity	**Local**	Maximum probing depth ≤4 mm Mostly horizontal bone loss	Maximum probing depth ≤5 mm Mostly horizontal bone loss	In addition to stage II complexity: Probing depth ≥6 mm Vertical bone loss ≥3 mm Furcation involvement Class II or III Moderate ridge defect	In addition to stage III complexity: Need for complex rehabilitation due to: Masticatory dysfunction Secondary occlusal trauma (tooth mobility degree ≥2) Severe ridge defect Bite collapse, drifting, flaring Less than 20 remaining teeth (10 opposing pairs)
Extent and distribution	**Add to stage as descriptor**	For each stage, describe extent as localized (<30% of teeth involved), generalized, or molar/incisor pattern			

TABLE 1B Classification of periodontitis based on grades that reflect biologic features of the disease including evidence of, or risk for, rapid progression, anticipated treatment response, and effects on systemic health

Periodontitis grade			Grade A: Slow rate of progression	Grade B: Moderate rate of progression	Grade C: Rapid rate of progression
Primary criteria	Direct evidence of progression	Longitudinal data (radiographic bone loss or CAL)	Evidence of no loss over 5 years	<2 mm over 5 years	≥2 mm over 5 years
	Indirect evidence of progression	% bone loss/age	<0.25	0.25 to 1.0	>1.0
		Case phenotype	Heavy biofilm deposits with low levels of destruction	Destruction commensurate with biofilm deposits	Destruction exceeds expectation given biofilm deposits; specific clinical patterns suggestive of periods of rapid progression and/or early onset disease (e.g., molar/incisor pattern; lack of expected response to standard bacterial control therapies)
Grade modifiers	Risk factors	Smoking	Non-smoker	Smoker <10 cigarettes/day	Smoker ≥10 cigarettes/day
		Diabetes	Normoglycemic/ no diagnosis of diabetes	HbA1c <7.0% in patients with diabetes	HbA1c ≥7.0% in patients with diabetes

JOURNAL OF Periodont

TABLE 1A Classification of periodontitis based on stages defined by severity (according to the level of radiographic bone loss and tooth loss), complexity and extent and distribution

Periodontitis stage		Stage I	Stage II	Stage III	Stage IV
Severity	Interdental CAL at site of greatest loss	1 to 2 mm	3 to 4 mm	≥5 mm	≥5 mm
	Radiographic bone loss	Coronal third (<15%)	Coronal third (15% to 33%)	Extending to mid-t of root and beyo	Extending to mid-third of root and beyond
	Tooth loss	No tooth loss due to periodontitis		Tooth loss due to periodontitis of ≤4 teeth	Tooth loss due to periodontitis of ≥5 teeth
Complexity	Local	Maximum probing depth ≤4 mm Mostly horizontal bone loss	Maximum probing depth ≤5 mm Mostly horizontal bone loss	In addition to stage II complexity: Probing depth ≥6 r Vertical bone loss ≥3 mm Furcation involvement Clas II or III Moderate ridge defect	In addition to stage III complexity: Need for complex rehabilitation due to: Masticatory dysfunction Secondary occlusal trauma (tooth mobility degree ≥2) Severe ridge defect Bite collapse, drifting, flaring Less than 20 remaining teeth (10 opposing pairs)
Extent and distribution	Add to stage as descriptor	For each stage, describe extent as localized (<30% of teeth involv pattern			

Quanto possono esserci utili tutte queste registrazioni nel ridefinire la DVO ?





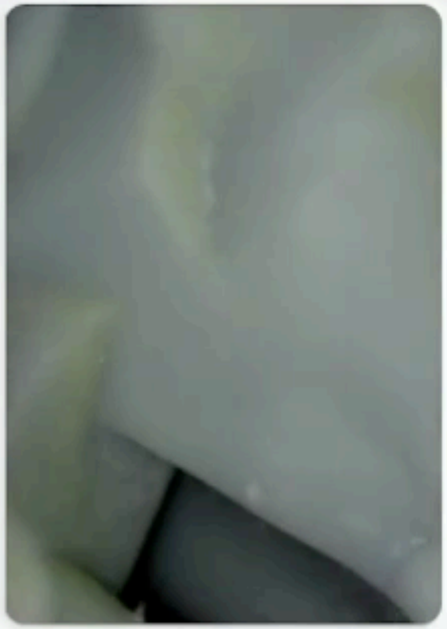

SHINING3D

PM 02:15:11

Nuovo ordine
Rossato Maurizio

Scansione
In corso

Previsualizzazione
-

Invia
-

DIEGO LONGHIN

18

01:20




Gruppi
Antagonista
Scansioni mascellari
Abutment di scansione
Porzioni di impianto
Abutments
Canali delle viti
Scansione "prelimatura/situ"
Waxup virtuale basale
Scansione facciale
Scansioni gengiva
Parti di progettazione di gengiva
Spessore min.
Tutte le altre parti
Anatomia completa
Waxup automatico
Parti finite
Oggetto per visualizzazione
sfera monson.stl (16-...-26)
MODELLO PRE.stl (16-...-26,37...
ROSSATO MAURIZIO.stl (16-.....
Registrazione occlusale
Parte interna coronale
mandibola.stl (37-...-47)
Denti
Nascosto
Visualizza
Copri-Autom.
INTERSEZIONE
-1
-0,88
-0,75
-0,62
-0,5
-0,38
-0,25
-0,12
4
Salva
Wizard
Strumenti
Mostra distanza
TruSmile
Vista in sezione
Aggiungi vista personalizzata

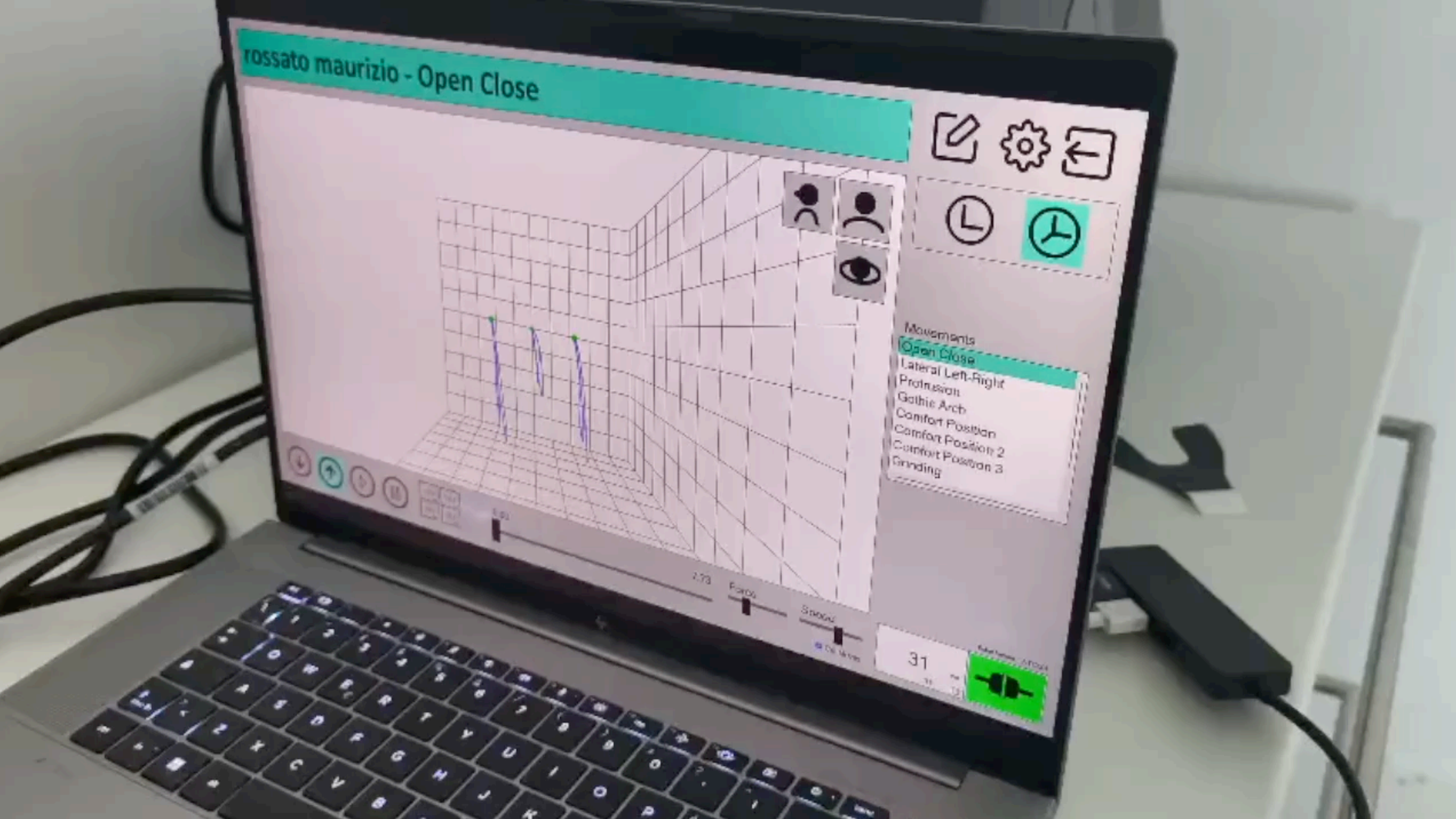
rossato maurizio - Open Close
Movements
Open Close
Lateral Left-Right
Protrusion
Gothic Arch
Comfort Position
Comfort Position 2
Comfort Position 3
Grinding
31








8.5





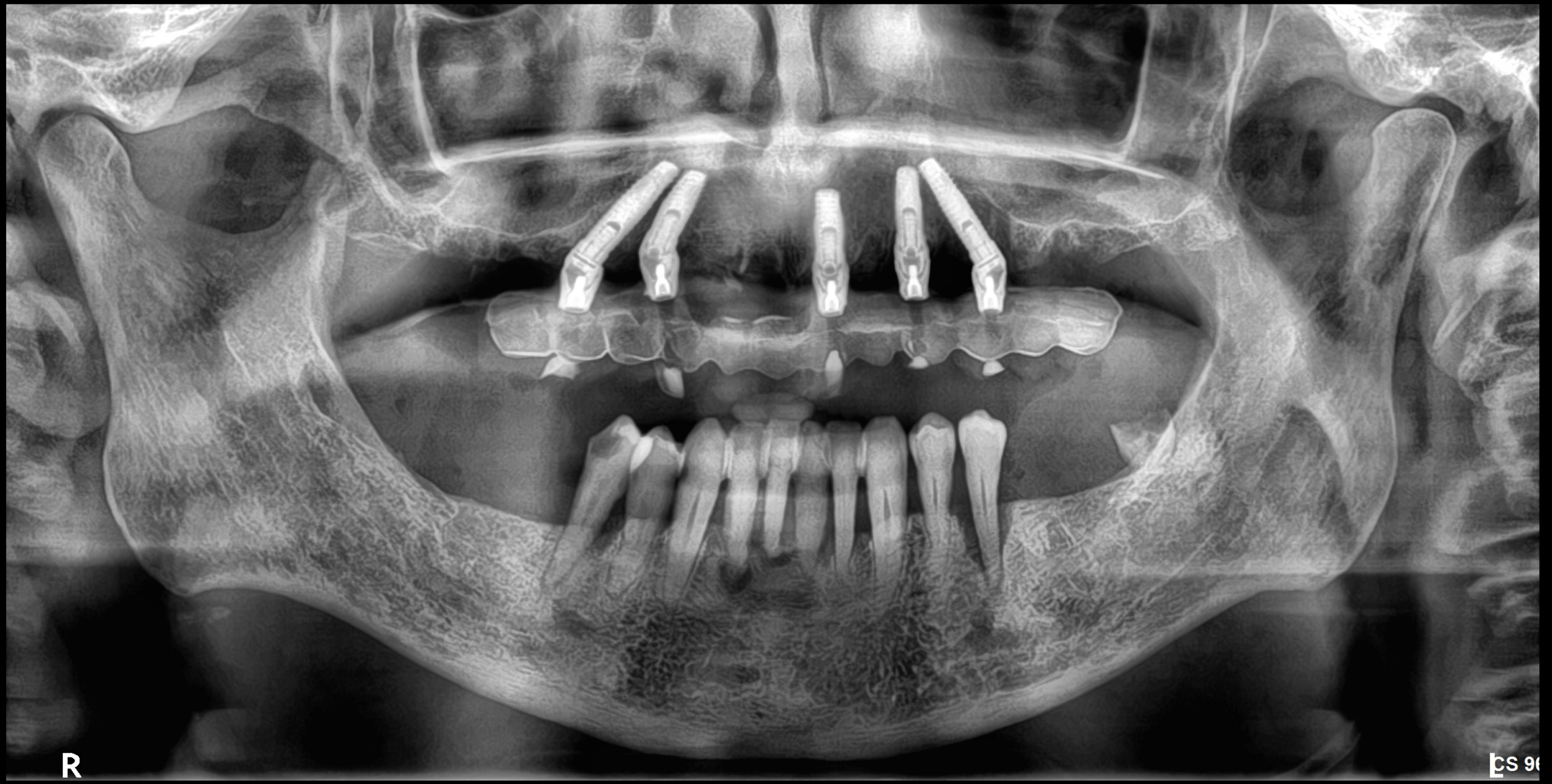
R
L
CS 9





Concludendo facciamo alcune valutazioni





Cone beam

a tuttí ?

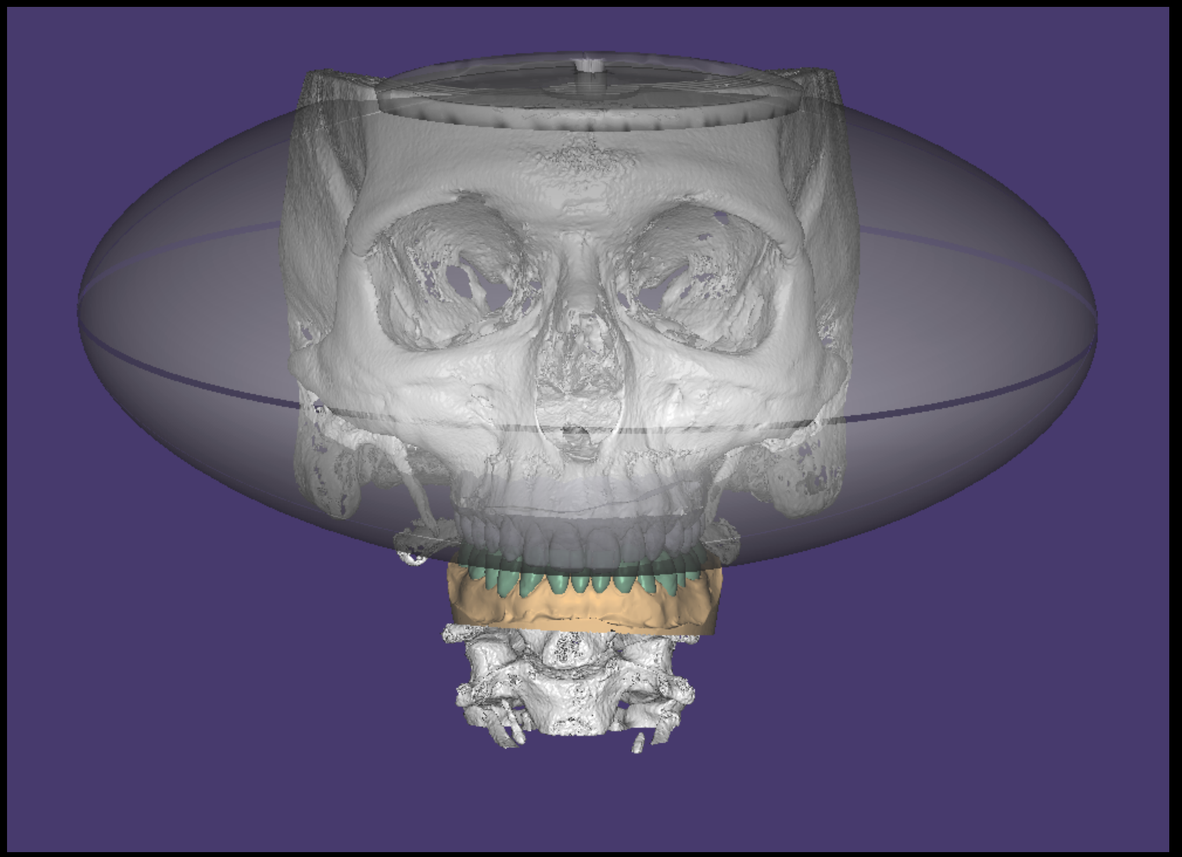

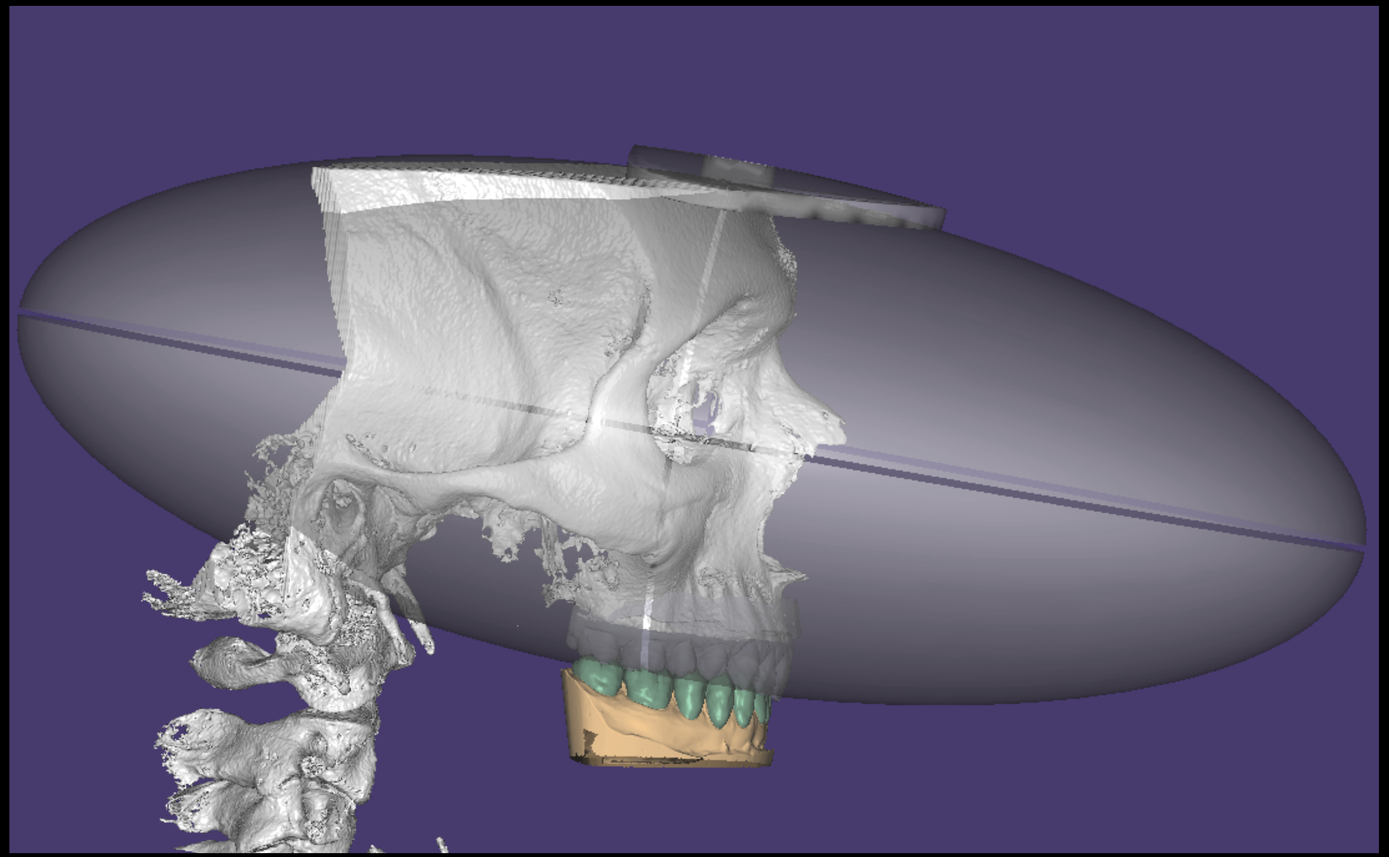



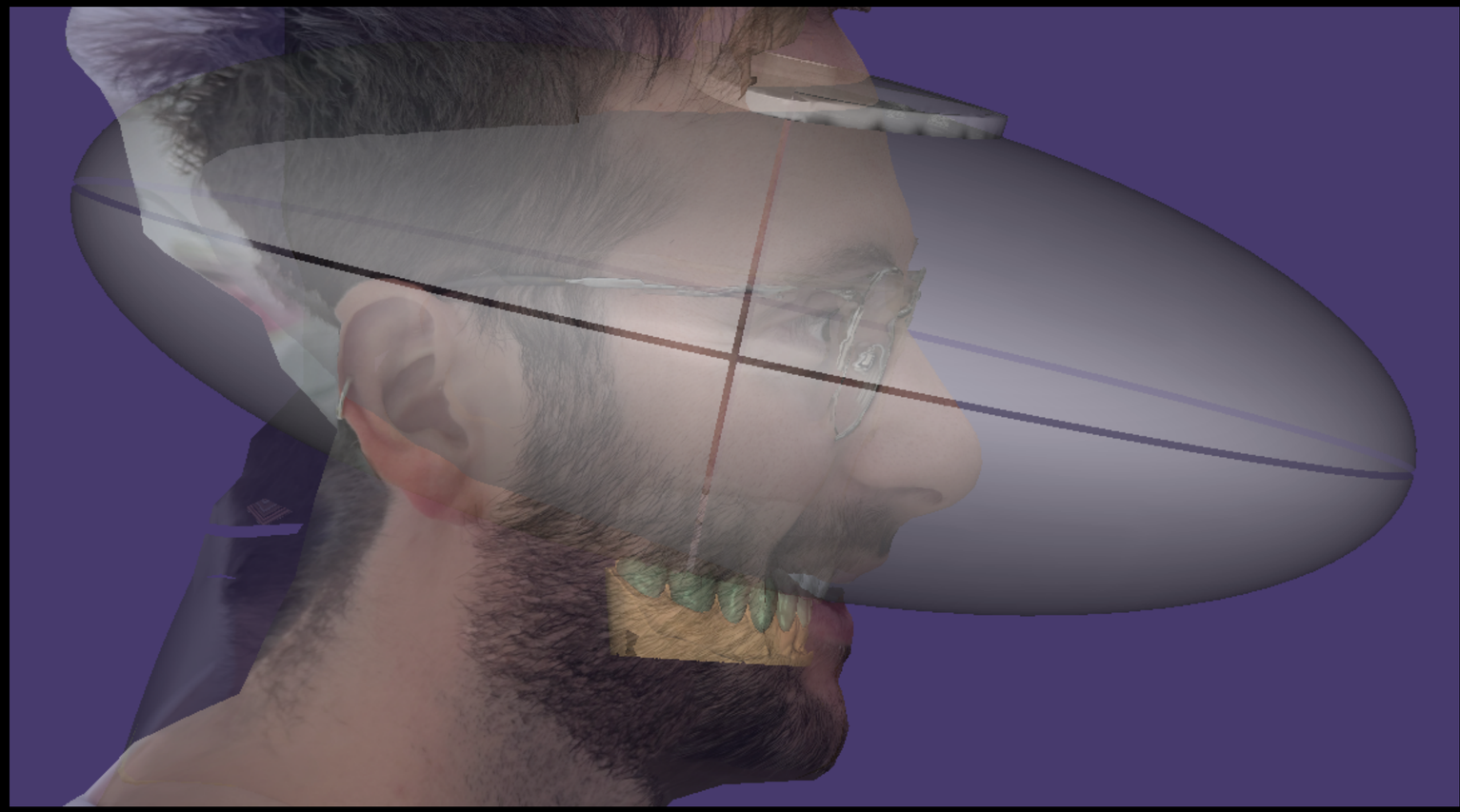

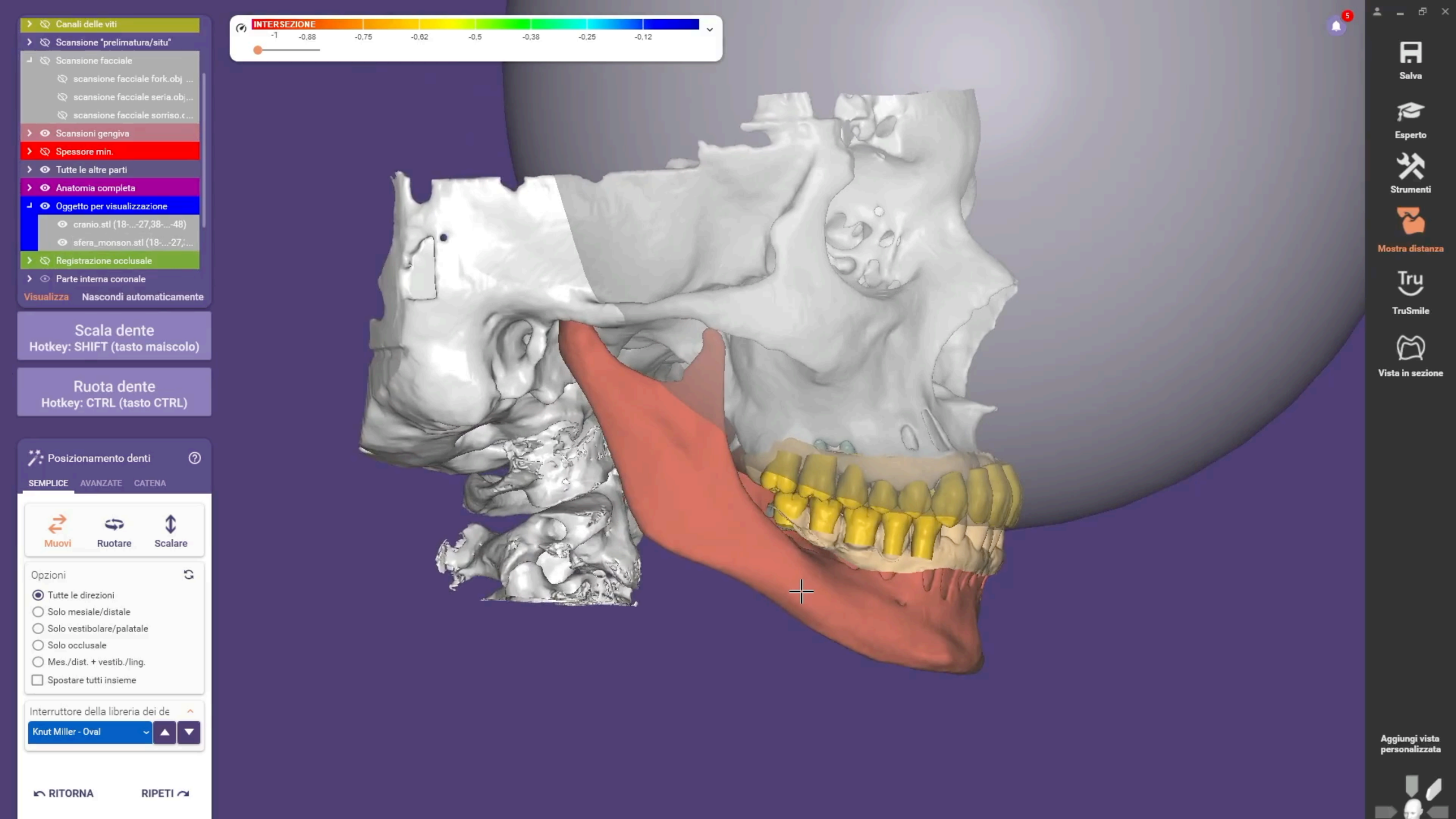
INTERSEZIONE
-1
-0,88
-0,75
-0,62
-0,5
-0,38
-0,25
-0,12
Canali delle viti
Scansione "prelimatura/situ"
Scansione facciale
scansione facciale fork.obj ...
scansione facciale seria.obj...
scansione facciale sorriso.c...
Scansioni gengiva
Spessore min.
Tutte le altre parti
Anatomia completa
Oggetto per visualizzazione
cranio.stl (18-...-27,38-...-48)
sfera_monson.stl (18-...-27,...
Registrazione occlusale
Parte interna coronale
Visualizza
Nascondi automaticamente
Scala dente
Hotkey: SHIFT (tasto maiscolo)
Ruota dente
Hotkey: CTRL (tasto CTRL)
Posizionamento denti
SEMPLICE
AVANZATE
CATENA
Muovi
Ruotare
Scalare
Opzioni
Tutte le direzioni
Solo mesiale/distale
Solo vestibolare/palatale
Solo occlusale
Mes./dist. + vestib./ling.
Spostare tutti insieme
Interruttore della libreria dei de
Knut Miller - Oval
RITORNA
RIPETI
Salva
Esperto
Strumenti
Mostra distanza
TruSmile
Vista in sezione
Aggiungi vista personalizzata

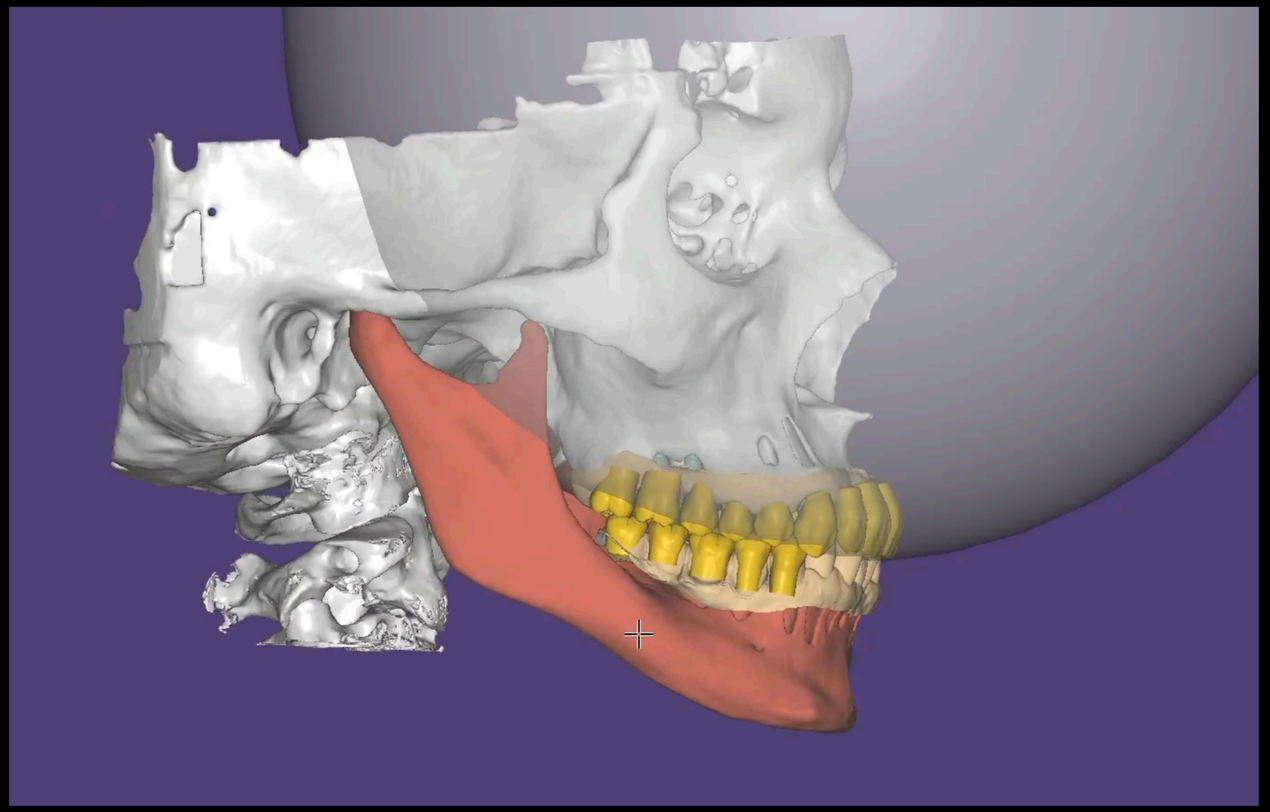

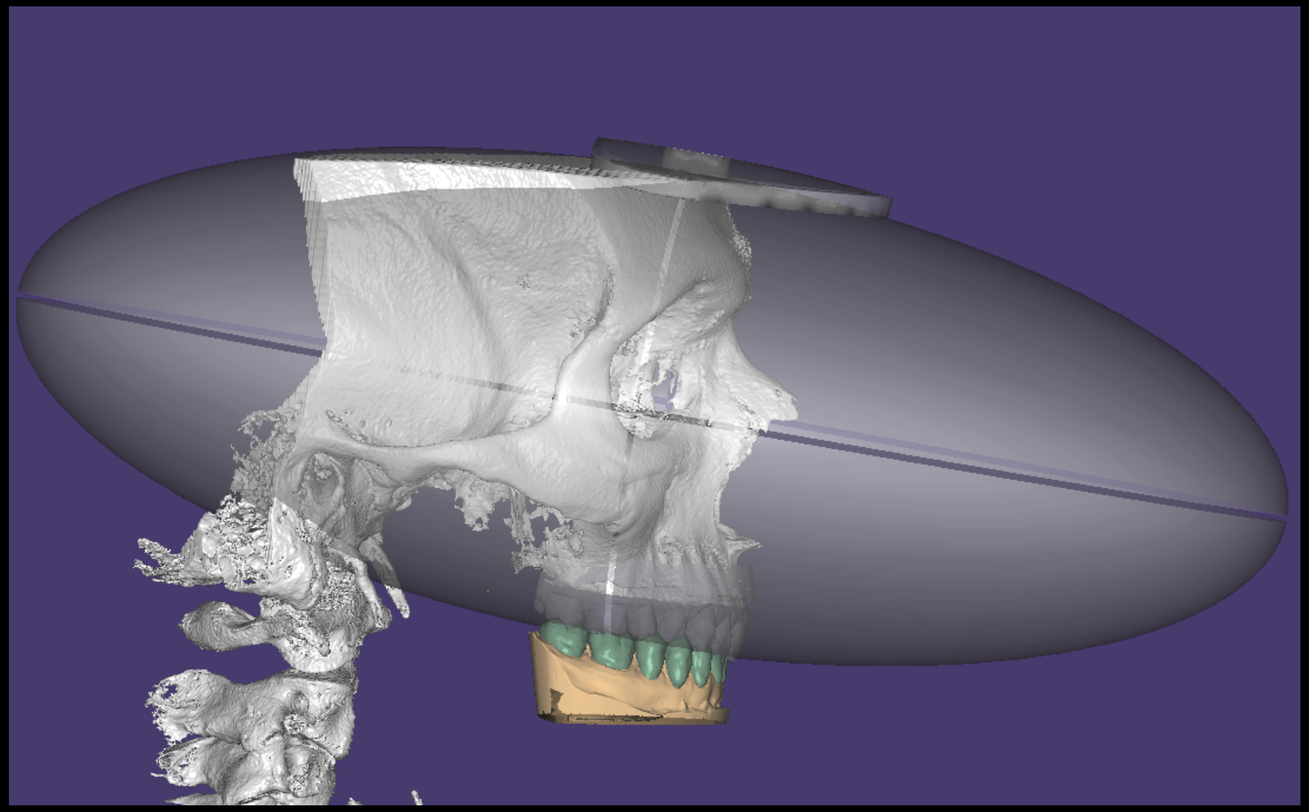

Conclusioni

Estetica e proporzioni auree



Conclusioni

Ricerca DVO

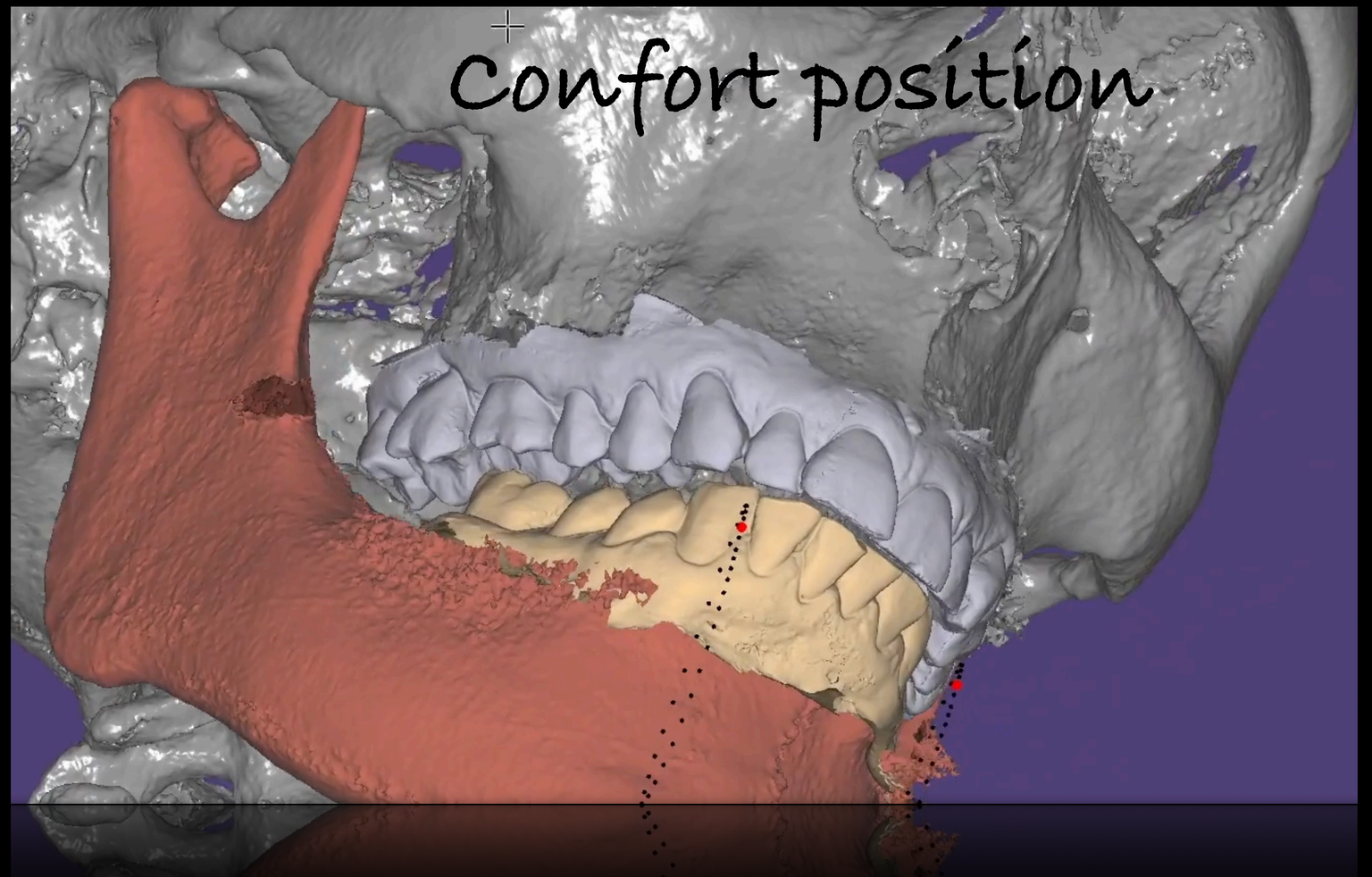

Movimento libero

- Possibilita’ di registrare la disfunzione e valutazione dei dati
- Valutazione dei dati registrati successivamente
- ad una placca o rebalancer di riprogrammazione
- Possibile ricattura della DVO in posizione Neuromuscolare
- (Comfort position)
- Rispetto delle asimmetrie craniali e posturali
- Verifica dei tracciati funzionali che possono essere utilizzati
- per finalizzare la protesi
- Utilizzo dei datti acquisiti di movimento libero anche su
- articolatore robotico (Artur) per costruire o finalizzare le protesi
- con movimenti propri del paziente
- Rispetto dei tracciati unici di ogni paziente


Marzia


Alex


Denis

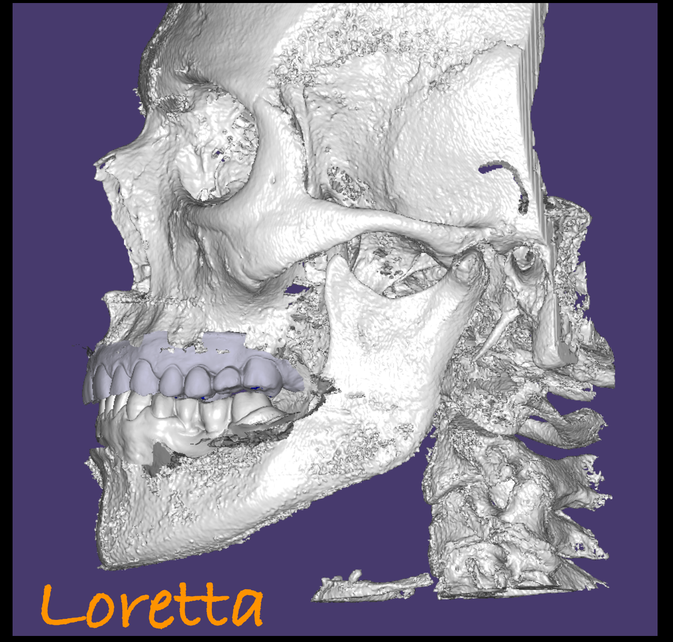
Loretta

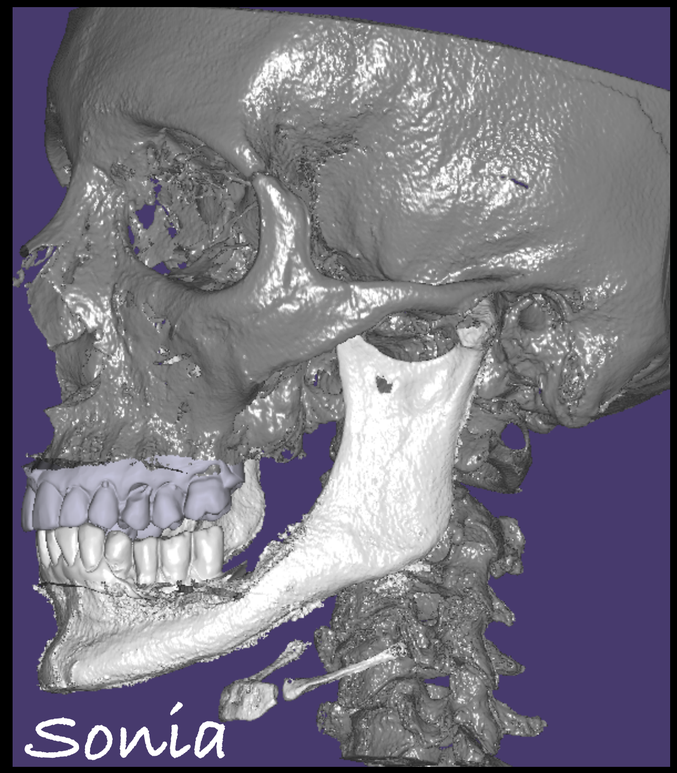
Sonia



Cosa c'è da aggiungere?

Reversibile

Conclusioni

Ricostruzione del piano occlusale
in base alle curve di compenso

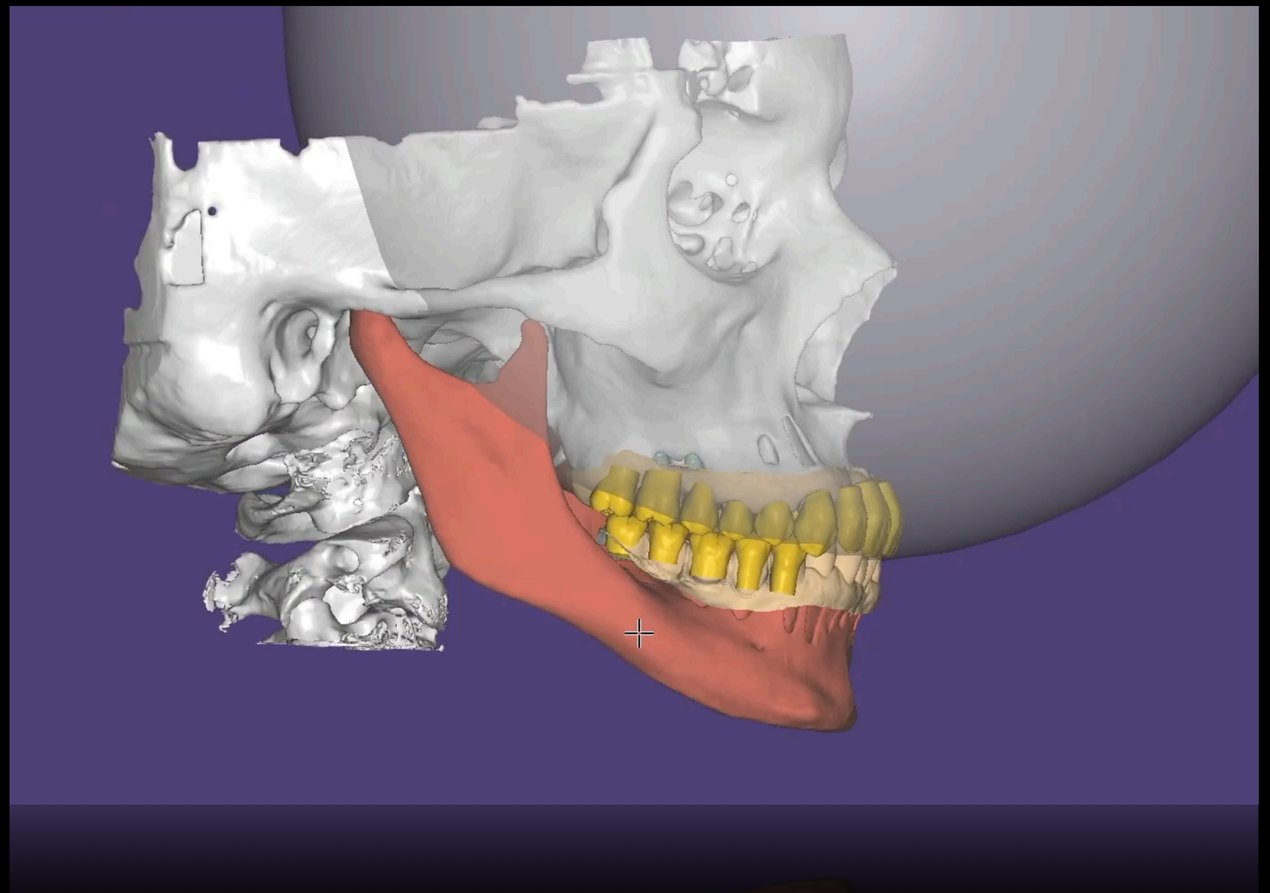

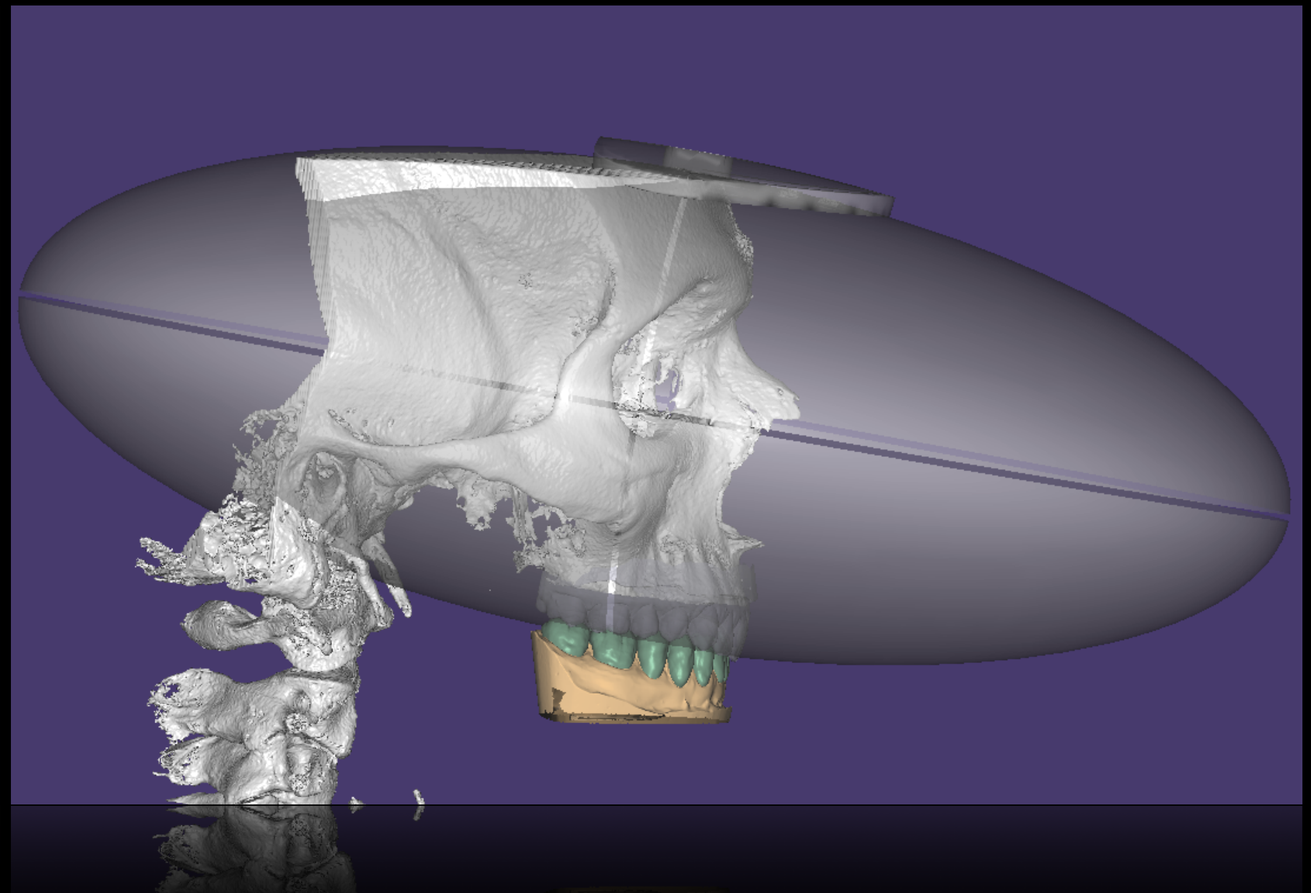

Conclusioni

Modellazione funzionale dinamica

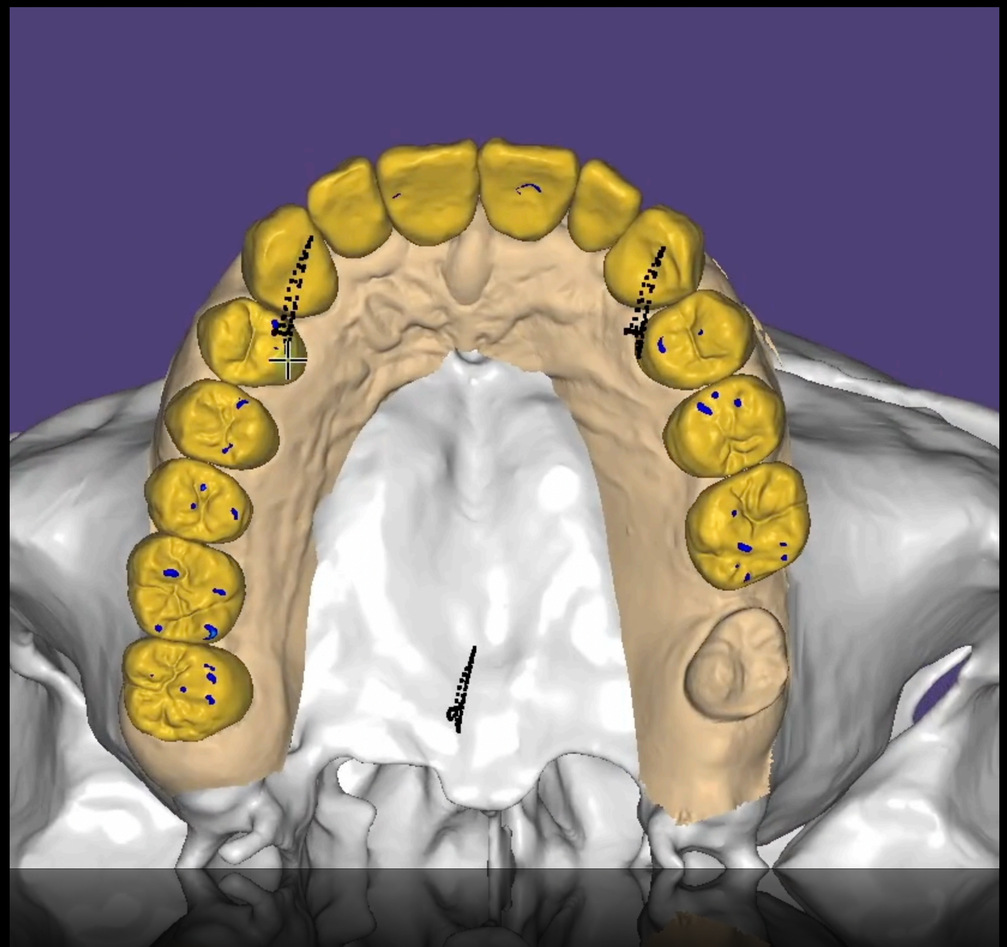

Conclusioni

Estetica e proporzioni auree

Ricerca DVO

Ricostruzione del piano occlusale in base alle curve di compenso

Modellazione funzionale dinamica

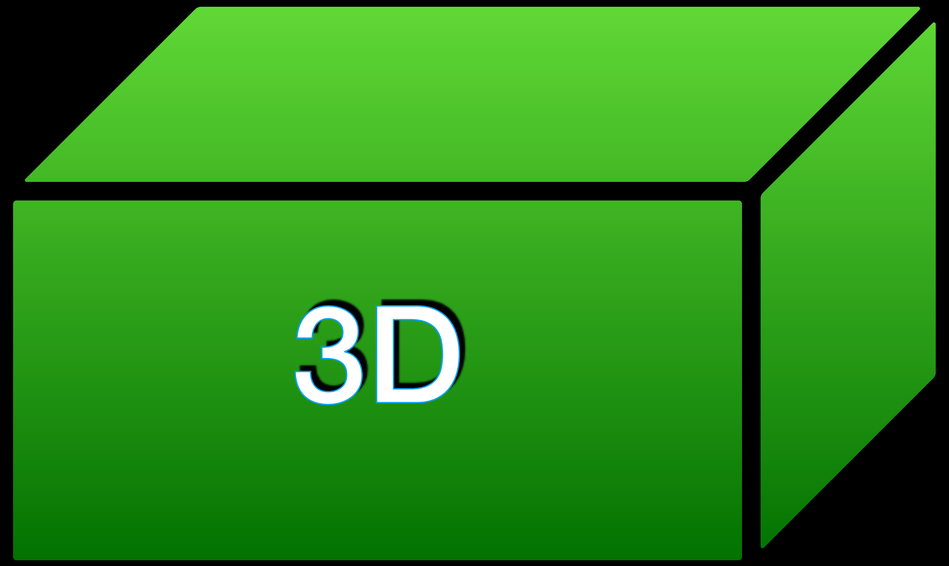

4D


Non sono sistemi solo per disfunzionali
Sono sistemi che non hanno confini



L'importante è non smettere di fare domande.

-- Albert Einstein

diego.longhin@virgilio.it

Grazie per l'attenzione